

Anchor Thighplasty

In the anchor thighplasty technique, the medial thigh lift is extended posteriorly into the infragluteal crease. The advantage is that the posterior thigh is lifted and ptosis of the caudal buttock can be corrected. Patients with buttock ptosis and medial thigh skin laxity without lateral thigh redundancy are ideal candidates. (*Aesthetic Surg J* 2004;24:61-64)

The aesthetic buttock has a symmetrical curvilinear fold that ends at the junction of the lateral thigh and posterior plane of the buttock. The medial thigh plane is flat from the posterior extent of the perineal crease to its transition with the anterior inguinal crease.

The aesthetic goal of a smooth inner thigh can be elusive. The techniques used to achieve this goal have, thus far, been lipoplasty and medial thigh lift. However, a medial thigh lift does not usually achieve complete correction of inner thigh laxity.¹ Furthermore, patients frequently desire a tighter posterior thigh and improvement of buttock contour.²

Pitanguy^{3,4} described a lateral incision extending to the anterior superior iliac spine. He used prone and supine positioning for correction of the medial thigh, posterior thigh, and hanging buttocks. He did not use fascial anchoring. Vilain⁵ corrected anterior medial thigh redundancy by pulling skin posteriorly using a supine and then prone approach. He used the prone approach only with deepithelialization of the supragluteal crease skin in subtrochanteric lipodystrophy.⁶ He did not use fascial anchoring. Lockwood¹ pulled the medial thigh skin redundancy anterior, using only the supine approach.

Fascial anchoring is used in medial thigh lifting techniques to limit scar displacement and to prevent tension on the labia.^{1,7,8} The drawbacks of the medial thigh lift are: (1) The ellipse of excised skin is limited posteriorly by the medial extent of the buttock fold, and (2) the posterior part of the closure is difficult to achieve with the patient supine.

Anchor Thighplasty

In anchor thighplasty, the anchor has 3 limbs or

hooks: Two represent the buttock creases and the third extends between the inner thighs. In this technique, the medial thigh lift is extended posteriorly into the infragluteal crease; the advantage is that the posterior thigh is lifted and ptosis of the caudal buttock can be corrected. The procedure can be performed as a combined inner thigh and posterior thigh lift or as a posterior thigh and buttockplasty alone. A buttock lift is an alternative procedure but results in a longer scar and carries an increased risk of morbidity.⁸

Patients with buttock ptosis and medial thigh skin laxity, without lateral thigh redundancy, are ideal candidates for the anchor thighplasty. End-stage liposuction patients with buttock laxity, medial thigh redundancy, and hollowed-out banana rolls will also benefit from this technique.

The resultant anchor thighplasty scar is hidden in the gluteal fold, except for the most lateral part, which extends to the lateral border of the gluteus medius. This lateral scar heals well and is in a favorable area for scar maturation. The posterior scar is curvilinear to replicate the gluteal fold. Surgical time and blood loss are less than those seen with a buttock lift.⁹

Surgical Technique

Mark the redundant skin of the lower buttock and superior thigh; outline the areas for fat injection or lipoplasty. Make vertical marks to help realign the wound margins after excising redundant tissue (*Figure 1, A-D*).

Perform the anterior portion of the surgery with the patient supine.¹ Apply posterosuperior traction on the thigh flap during closure. Abduct the patient's legs to about 15 degrees. (Do not use the frog-leg position; it causes distortion.) Leave the posterior portion of the



Laurence Kirwan, MD, Norwalk, CT, is a board-certified plastic surgeon and an ASAPS member.

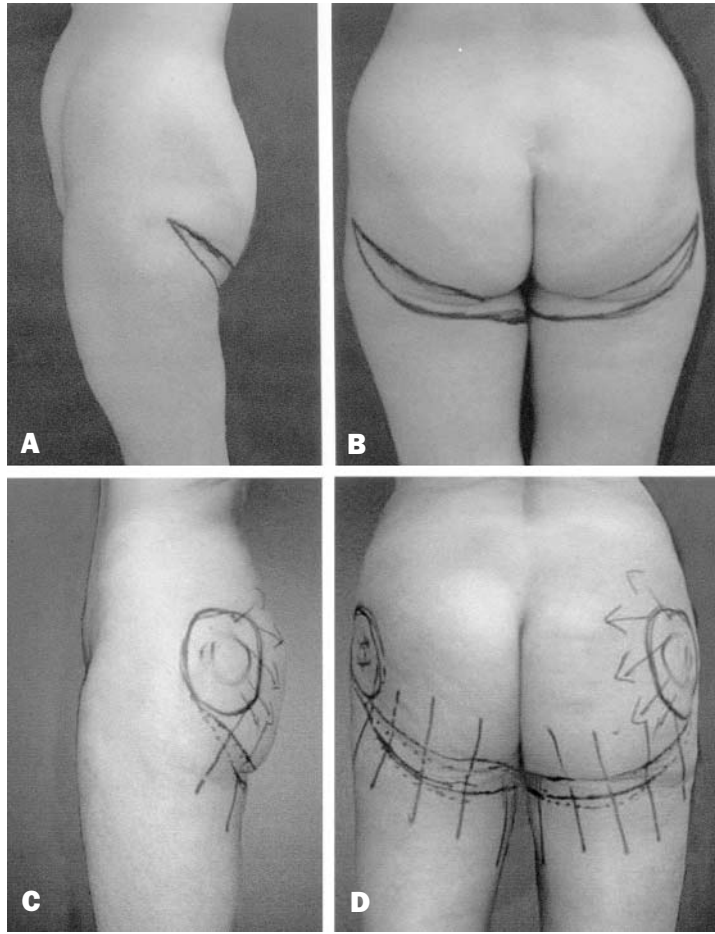


Figure 1. A-D, The redundant skin of the lower buttock and superior thigh is marked. Areas for fat injection or lipoplasty are also outlined, and cross marks are made at the site of skin excision.

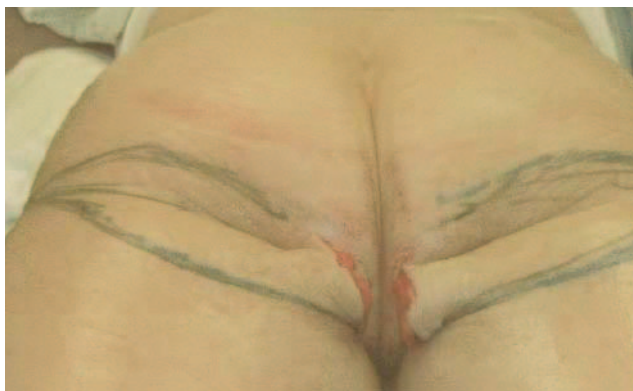

Figure 2. The posterior portion of the wound is left open and redundant skin left as a flap. The patient is then placed in the prone position.

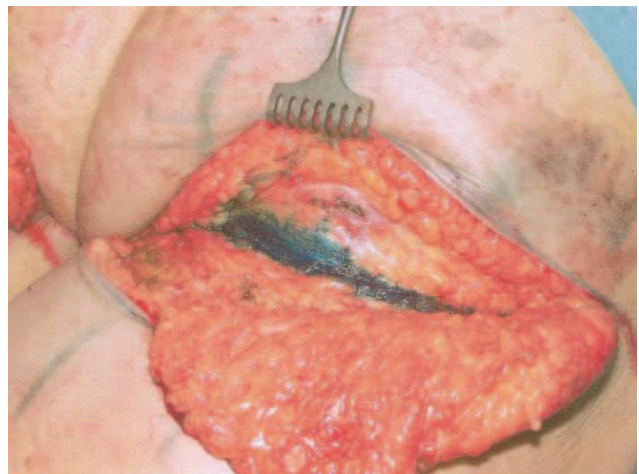


Figure 3. Closure is performed at the posterior thigh region with 0-Nurolon, catching the gluteus maximus at the level of the buttock crease, which is clearly visible and can be marked with methylene blue.

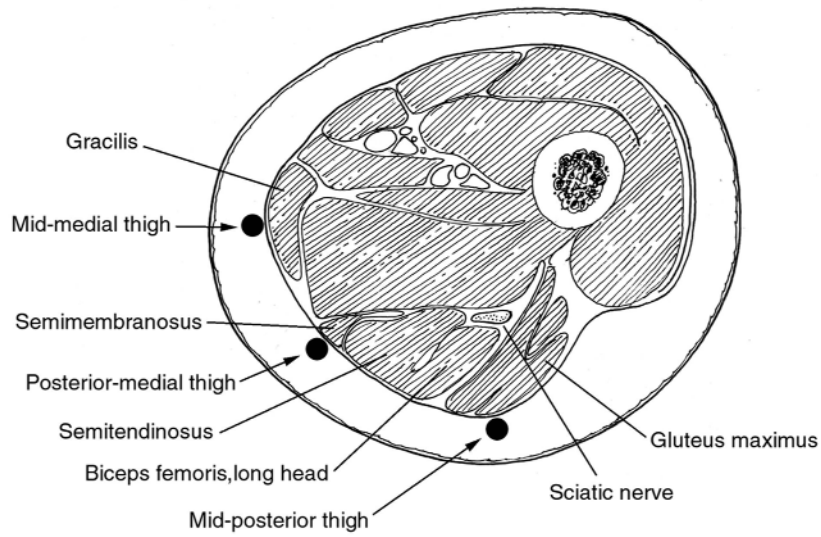


Figure 4. The 3 key points of suture suspension are the midmedial thigh, the midposterior thigh, and the posteromedial thigh. Points of suture suspension are marked.

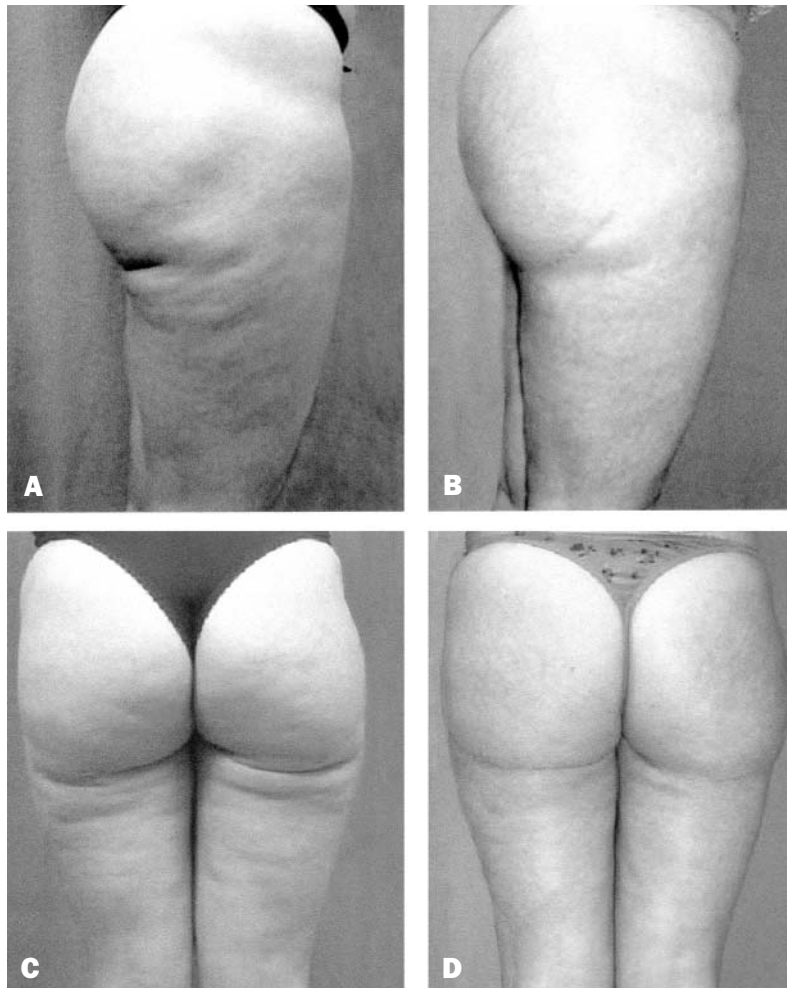


Figure 5. A, C, Preoperative views of a 38-year-old woman. **B, D,** Postoperative views 1 year after anchor thighplasty.

wound open, with redundant skin as a flap (Figure 2). Then turn the patient prone. Make an incision in the proximal line of the marking that indicates the new gluteal crease. This extends medially to the posterior point of the medial thigh skin excision and laterally to the anterior border of the gluteus maximus (anterior extent of buttock crease when buttock is displaced in a caudal direction).

Perform distal undermining at the deep fascial level. Begin posterior dissection over the gluteus maximus muscle laterally, using the cutting cautery to identify muscle contractions. Extend the dissection medially to join the medial thigh dissection extending over the proximal bellies of the adductor group.

The sciatic nerve is protected by the gluteus maximus proximally and laterally and the adductor group distally and medially. Complete undermining to a point 2 to 4 cm beyond the distal marking of the planned excision and apply cephalad traction to the distal flap. Trim the distal flap. Close with 0-Nurolon (Ethicon, Edinburgh, UK), grasping the gluteus maximus at the level of the buttock crease. This landmark is clearly visible and can be marked with methylene blue (Figure 3). Do not take a bite of the deep fascia laterally because this will cause tethering. Taper the skin excision medially to meet the medial thigh excision. Perform further closure using 0-Nurolon from medial to midline posteriorly and lateral to midline posteriorly extending to the previously placed suture in the midposterior thigh. Laterally, the pull of the thigh flap is in a posterosuperior direction. The 3 key points of deep

fascial suspension are the midmedial thigh, posterior-medial thigh, and midposterior thigh (Figure 4). Drains are not required because there is no residual dead space. Results of this procedure are shown in Figure 5.

Anchor thighplasty permits additional skin removal from the posterior medial thigh and the posterior thigh, suspending the superficial fascia of the thigh at key sites and correcting buttock ptosis and banana roll resulting from end-stage lipoplasty.

References

1. Lockwood T. Fascial anchoring technique in medial thigh lifts. *Plast Reconstr Surg* 1988;82:299-304.
2. Kirwan L. Shaping up: news about bodylifting. *Plastic Surgery Products Magazine*, May 2002.
3. Pitanguy I. Trochanteric lipodystrophy. *Plast Reconstr Surg* 1964;34:280-286.
4. Pitanguy I. Surgical reduction of the abdomen, thighs and buttocks. *Surg Clin North Am* 1971;51:479-489.
5. Vilain R. Use of dermal-fat flaps in treating abdominal scars in abdominoplasty and in subtrochanteric lipectomy. *Plast Reconstr Surg* 1977;60:876-881.
6. Candiani P, Campiglio GL, Signorini M. Fascio-fascial suspension technique in medial thigh lifts. *Aesthetic Plast Surg* 1995;19:137-140.
7. Hodgkinson DJ. Medial thighplasty: prevention of scar migration and labial flattening. *Aesthetic Plast Surg* 1989;13:111-114.
8. Lockwood TE. Buttock lift: the transverse lift with superficial fascial suspension. *Aesthetic Surg J* 1999;19:337-338.

Reprint requests: Dr. Laurence Kirwan, 605 West End Ave., Norwalk, CT 06850; e-mail: fcps.lk@att.net.

1090-820X/\$30.00

Copyright © 2004 by The American Society for Aesthetic Plastic Surgery, Inc.
doi:10.1016/j.asj.2003.10.003