

Body Contouring Surgery Guide to Management

Laurence Kirwan MD
Grand Rounds, Norwalk Hospital
September 20, 2023



Kirwan, Laurence MD, FRCS. Aesthetic Units and Zones of Adherence, Relevance to Planning Incisions in Body Contouring Surgery. Plastic & Reconstructive Surgery-Global Open 11(6):p e5093, June 2023. | DOI: 10.1097/GOX.00000000000005093

OPEN



ORIGINAL ARTICLE

Cosmetic

Aesthetic Units and Zones of Adherence, Relevance to Planning Incisions in Body Contouring Surgery

Laurence Kirwan, MD, FRCS

Background: Aesthetic units (AUs) and zones of adherence (ZAs) have been previously noted in the face and torso. A systematic classification of common AUs and

Download

KIRWAN
PLASTIC SURGERY

REFERENCES

Kirwan L. Anchor Thighplasty. Aesthetic Surgery Journal, 24/1 pp. 61-64, January/February 2004

Kirwan L. Breast Auto-Augmentation, Canadian Journal Plastic Surgery, 15(2) 73-76, 2007



massive weight loss (MWL)

- Self-induced: diet (80%) and exercise (20%)
- Semaglutide type drugs: Ozempic, Wegovy, Saxenda (liraglutide)
- Bariatric Surgery:
 - gastric band
 - sleeve gastrectomy
 - roux-en-Y gastric bypass


Indications for Body Contouring Surgery (BCS)

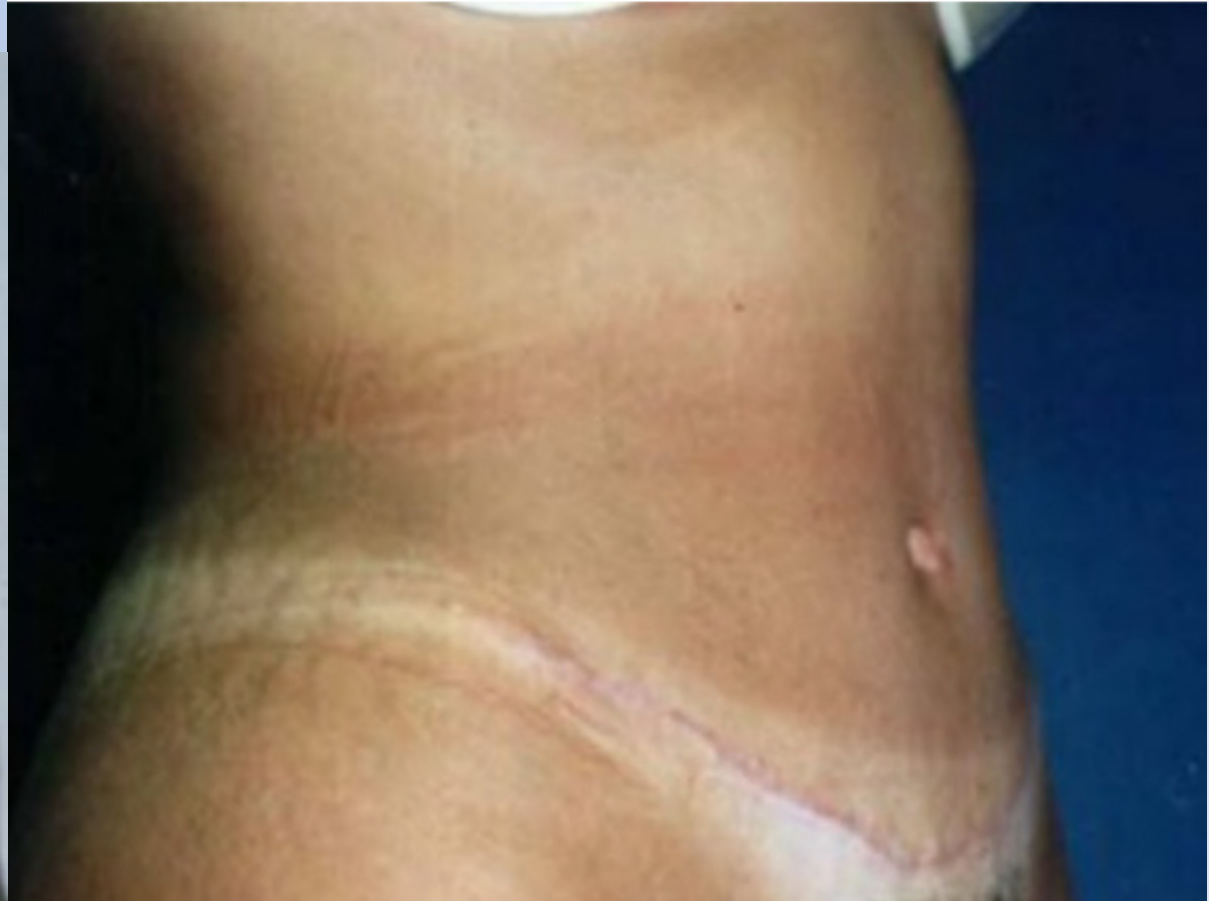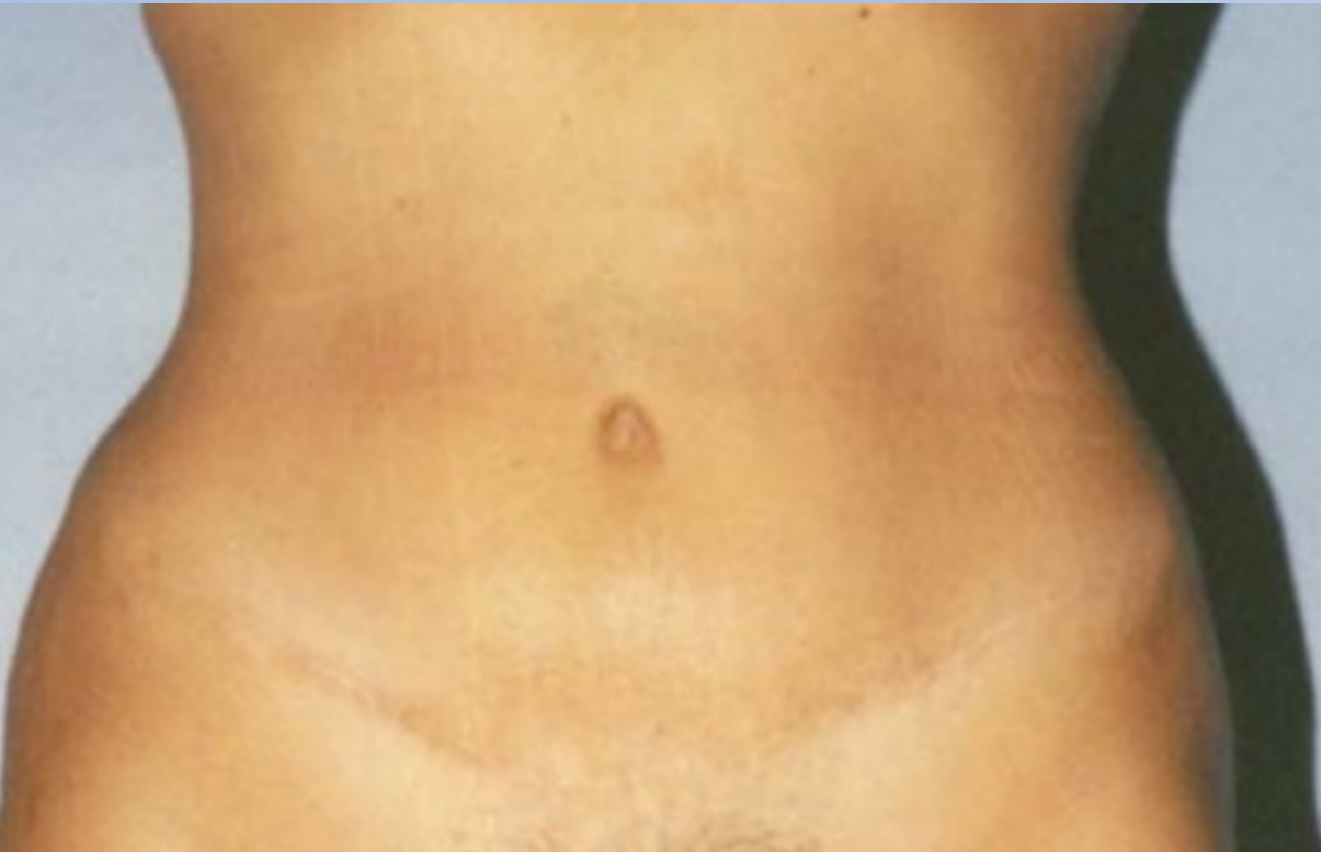- ✓ Massive Weight Loss (MWL)
- ✓ Pregnancy
- ✓ Breast feeding
- ✓ Ageing

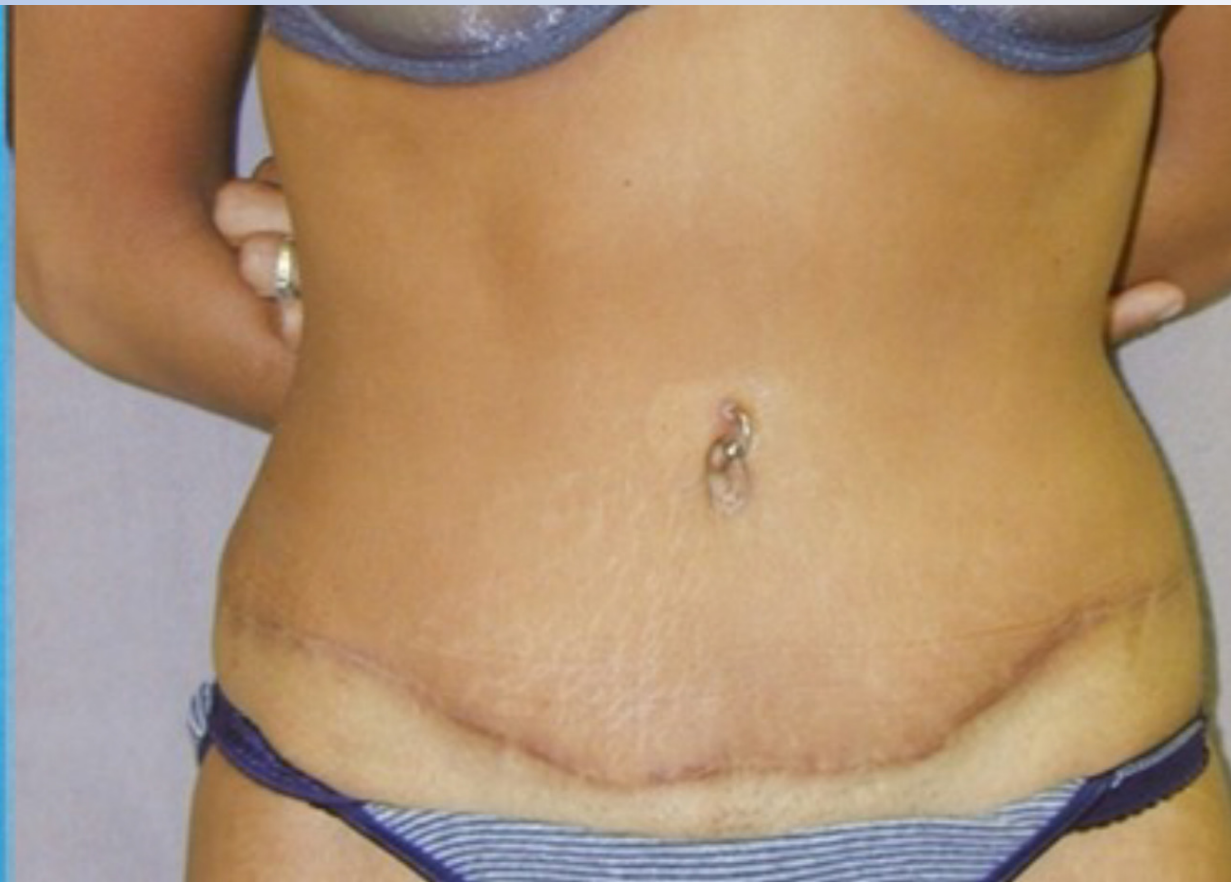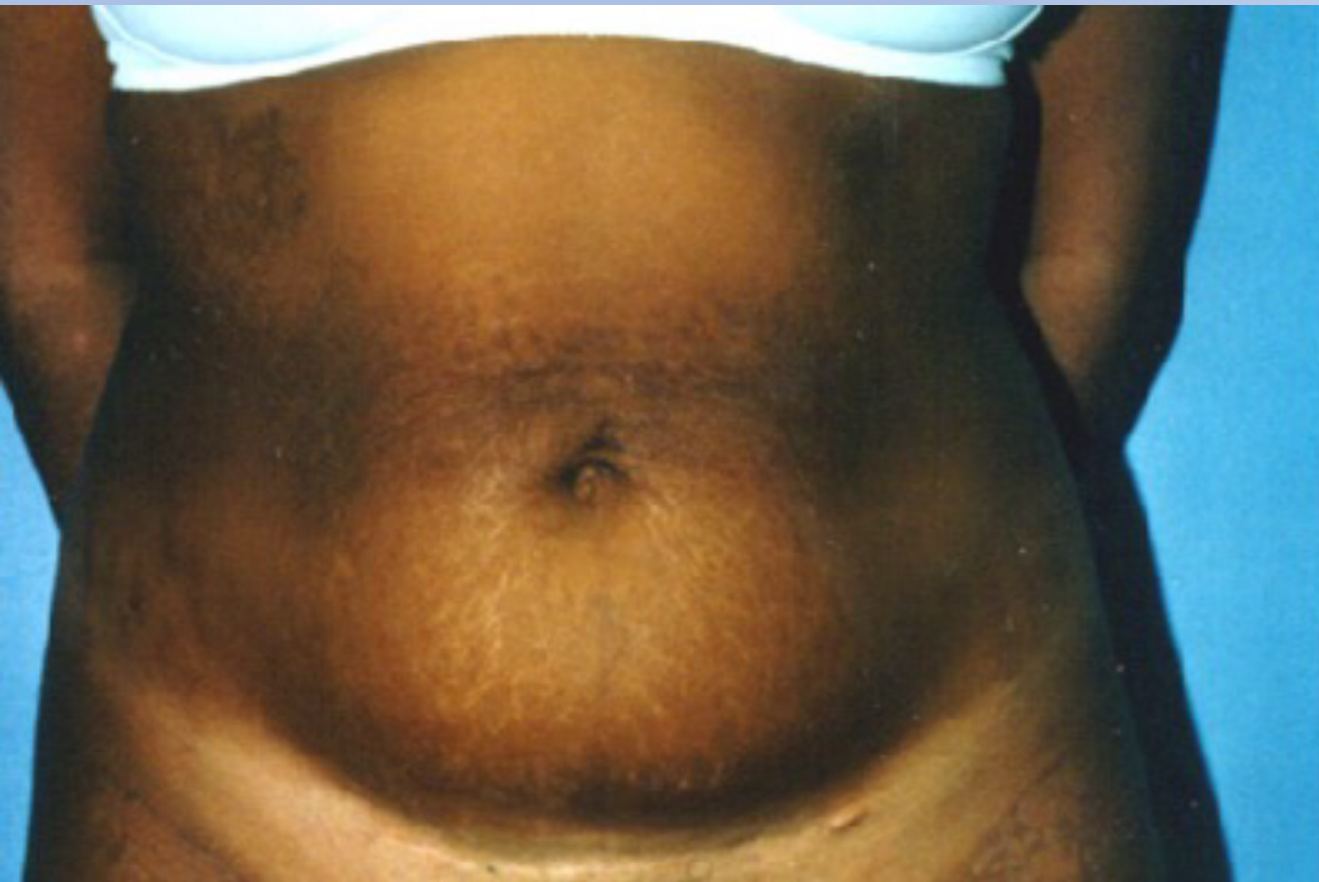What to do after weight loss

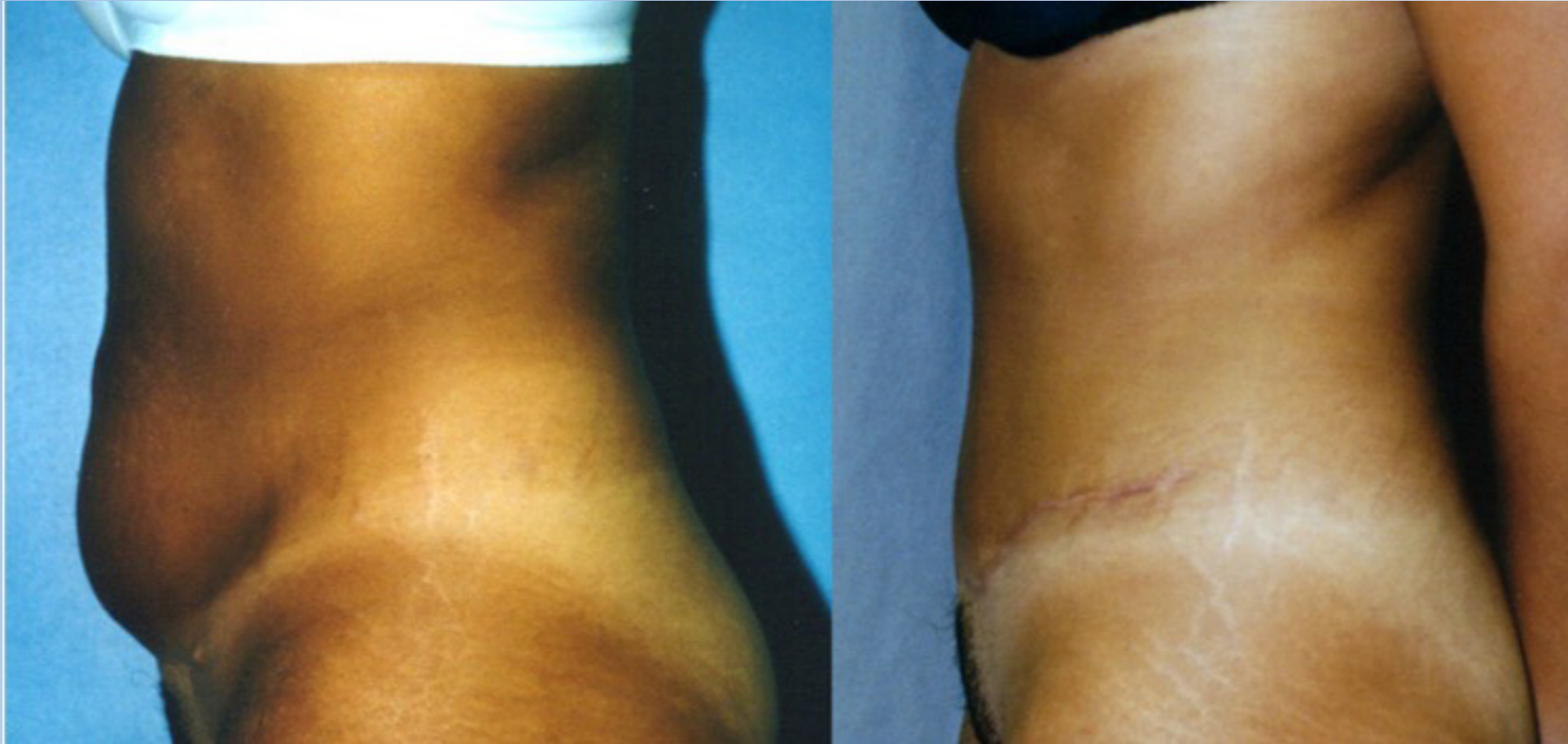

clothing choices and relationship to scar placement













**Stage
1**

LOWER BODY

**Stage
2A**

UPPER BODY

**Stage
2B**

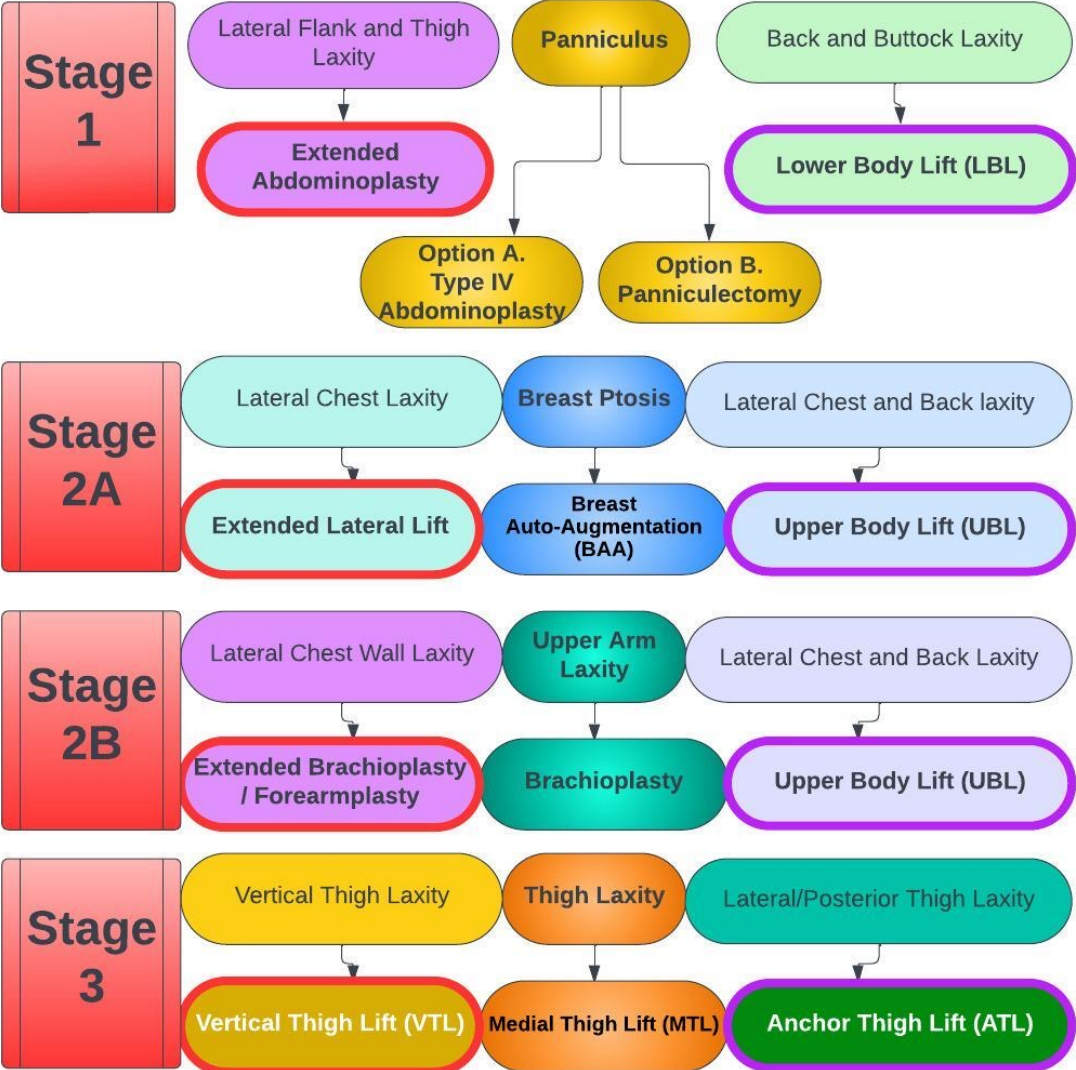
UPPER EXTREMITY

**Stage
3**

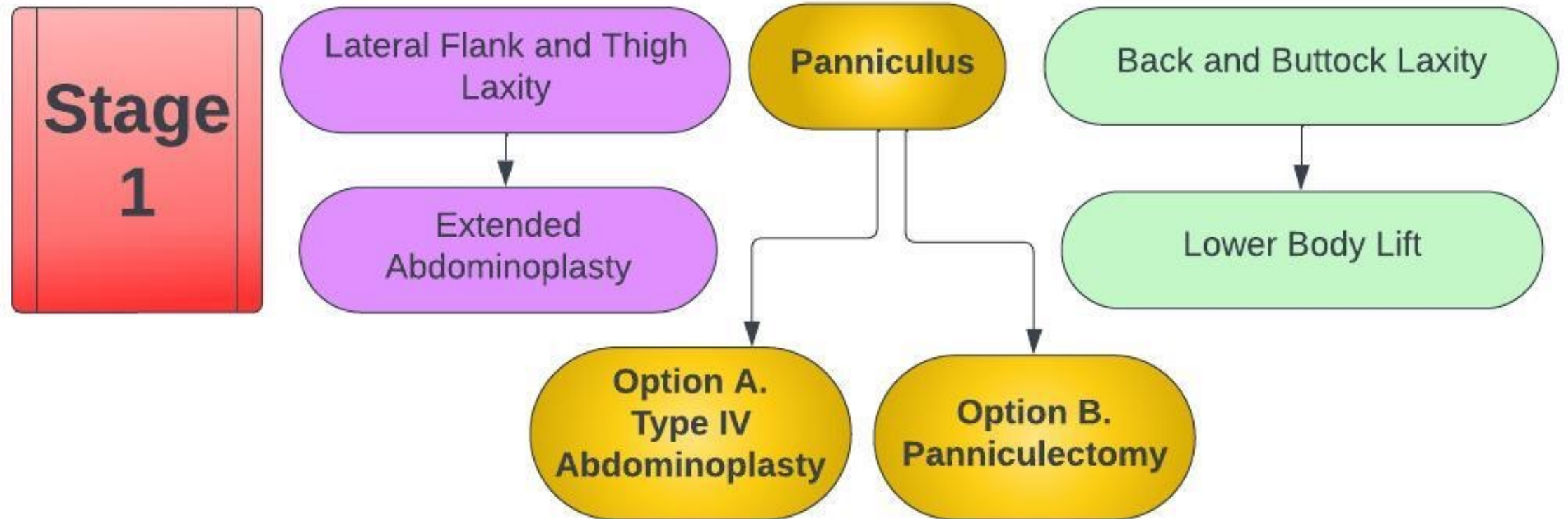
LOWER EXTREMITY

Massive Weight Loss (MWL)

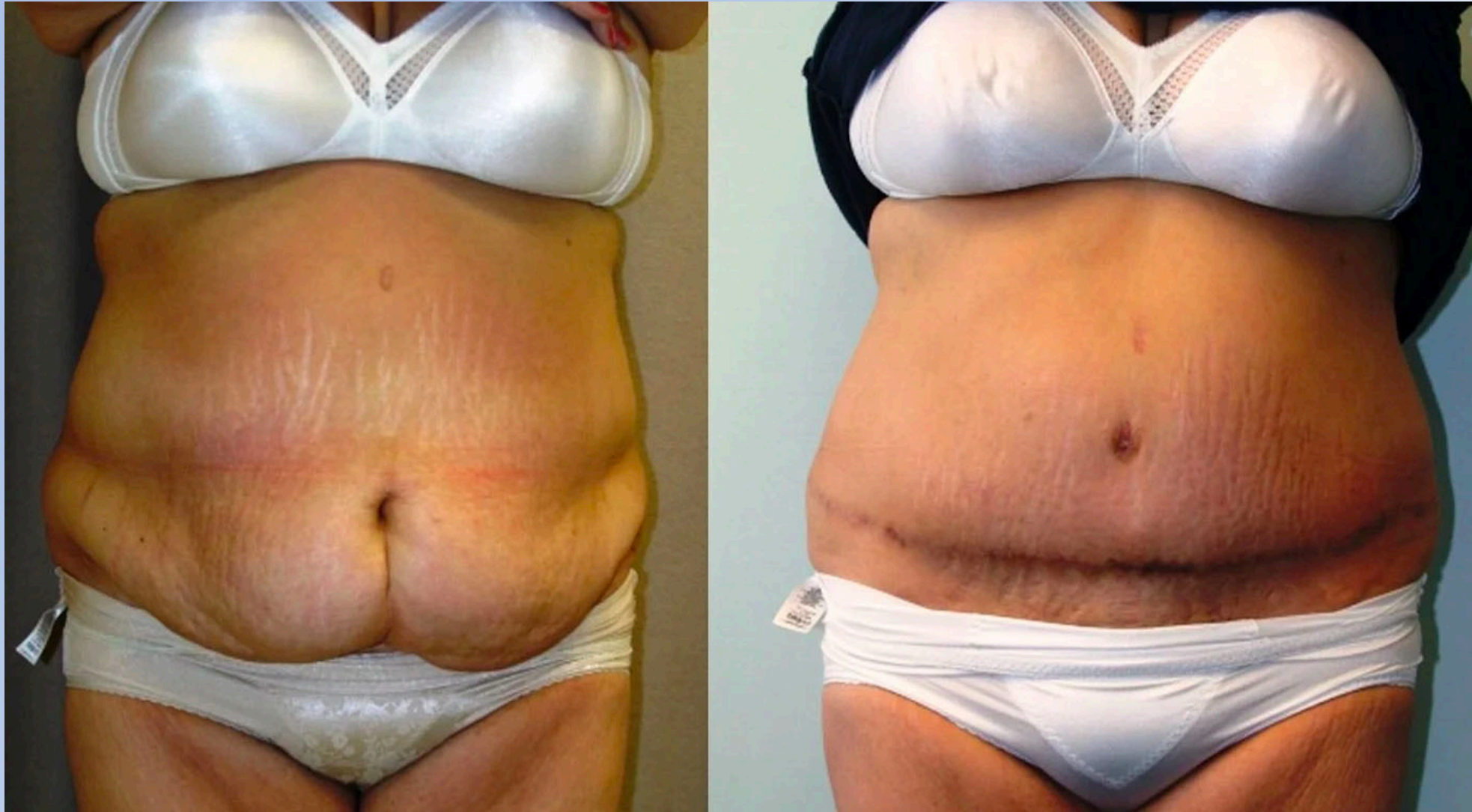Body Contouring Surgery



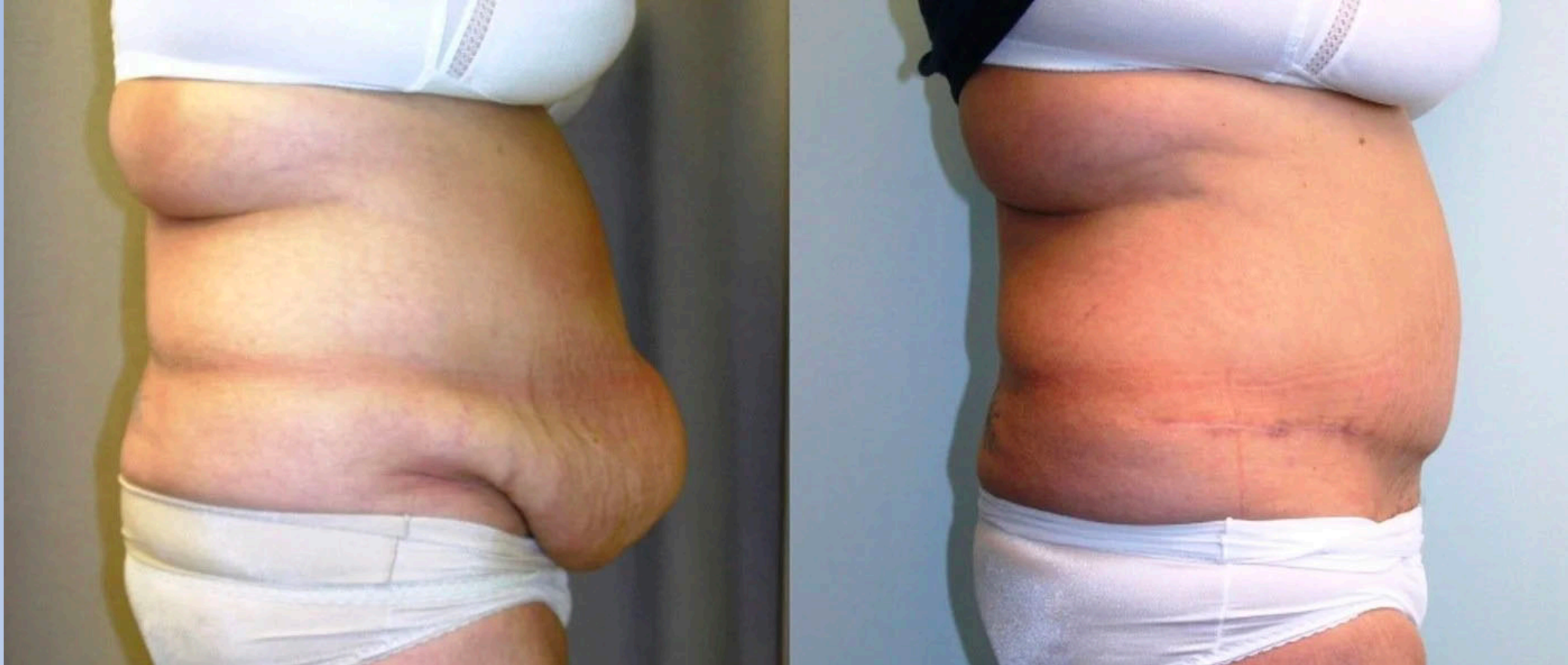Stage 1



Stage 1, Option B: Panniculectomy

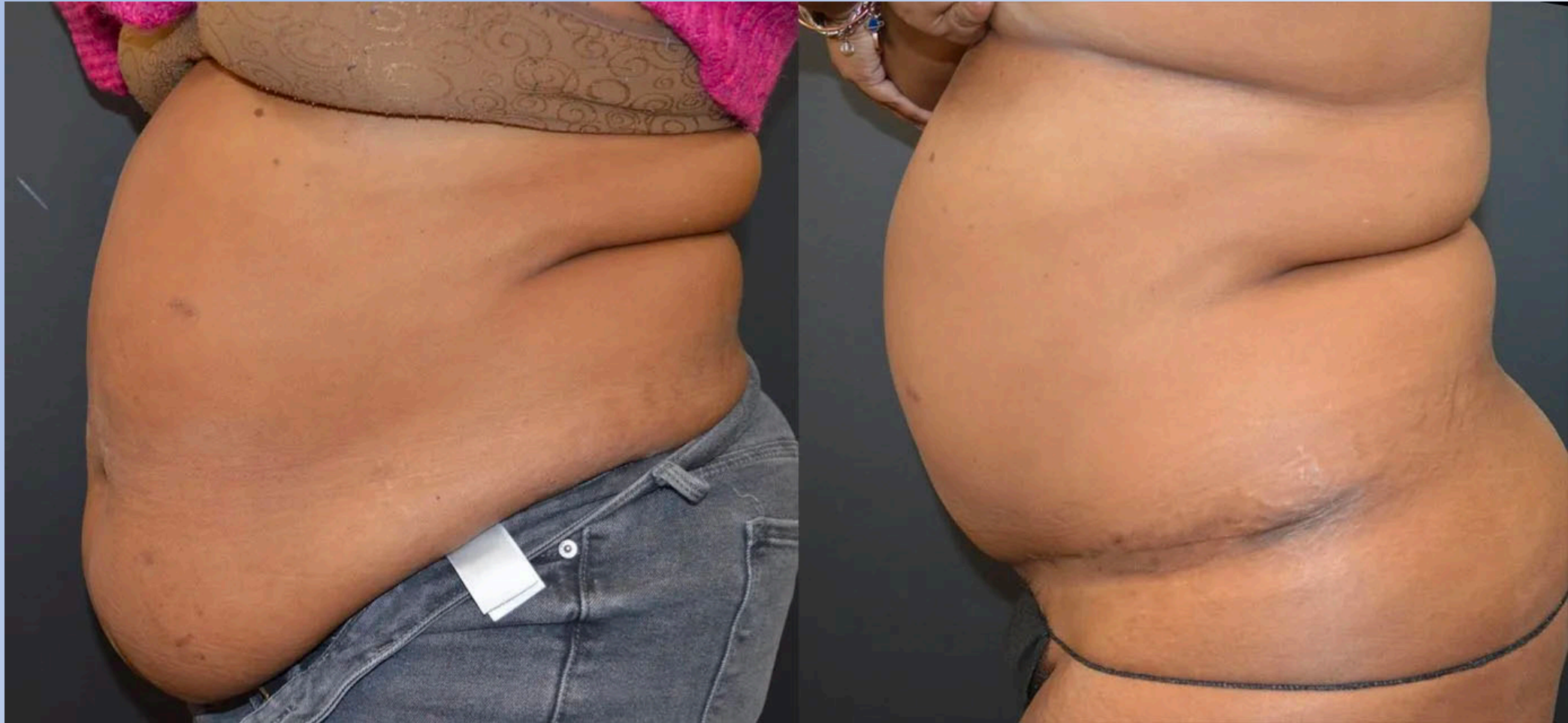

Stage 1, Option B: Panniculectomy

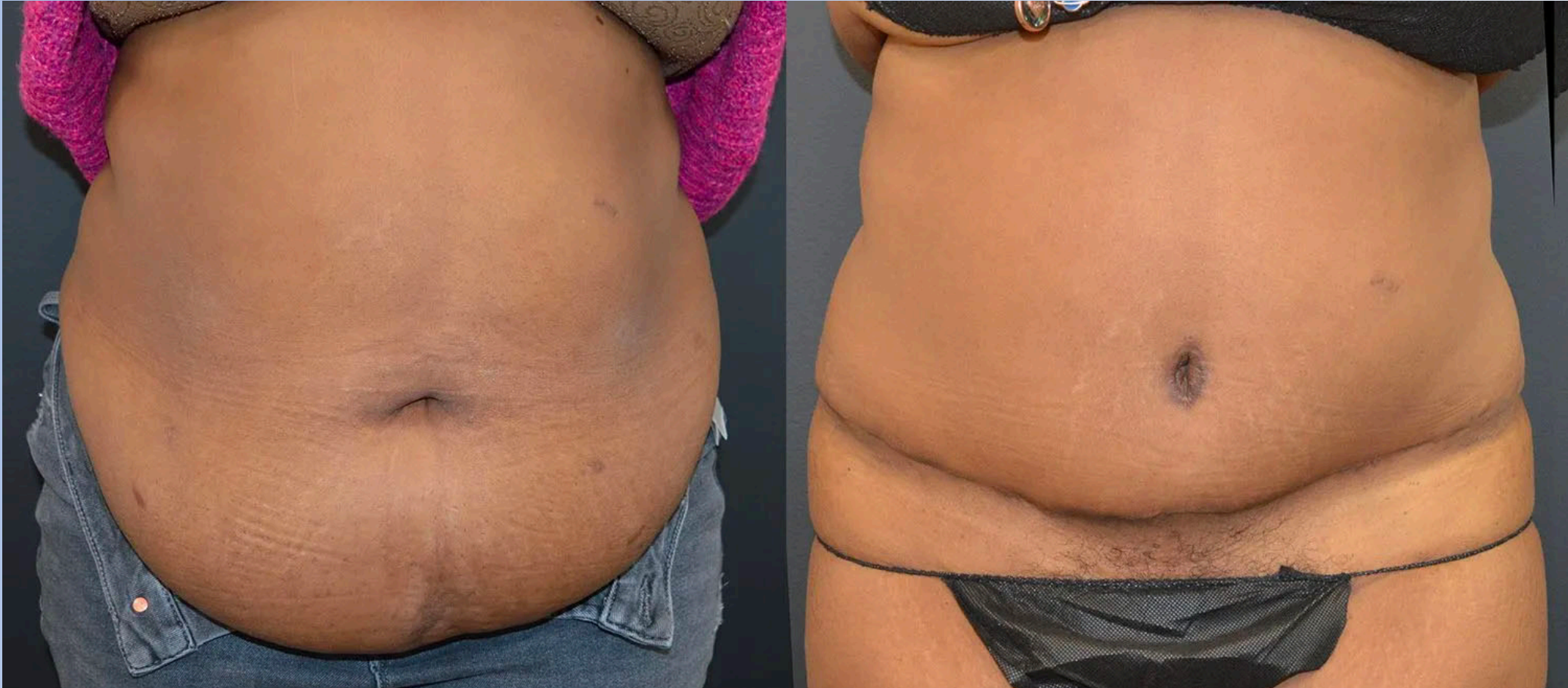

Stage 1, Option B: Panniculectomy. 42 year-old, African American. Female, 5'4." 7 months postoperative. 3000 gm excision. 900 cc Liposuction upper abdomen, 2 lb weight loss (218 lbs).

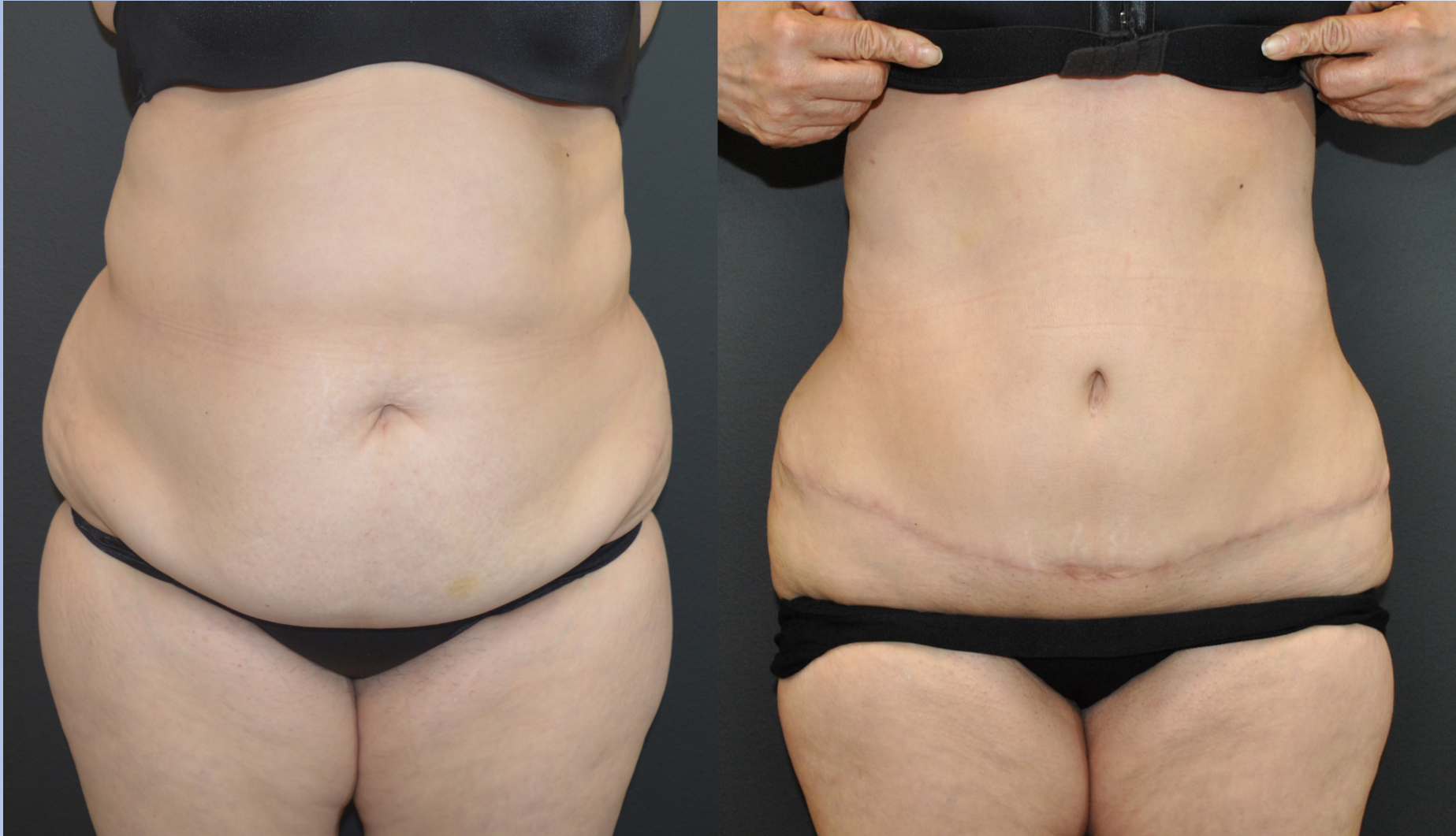BMI 37.8 to 37.4



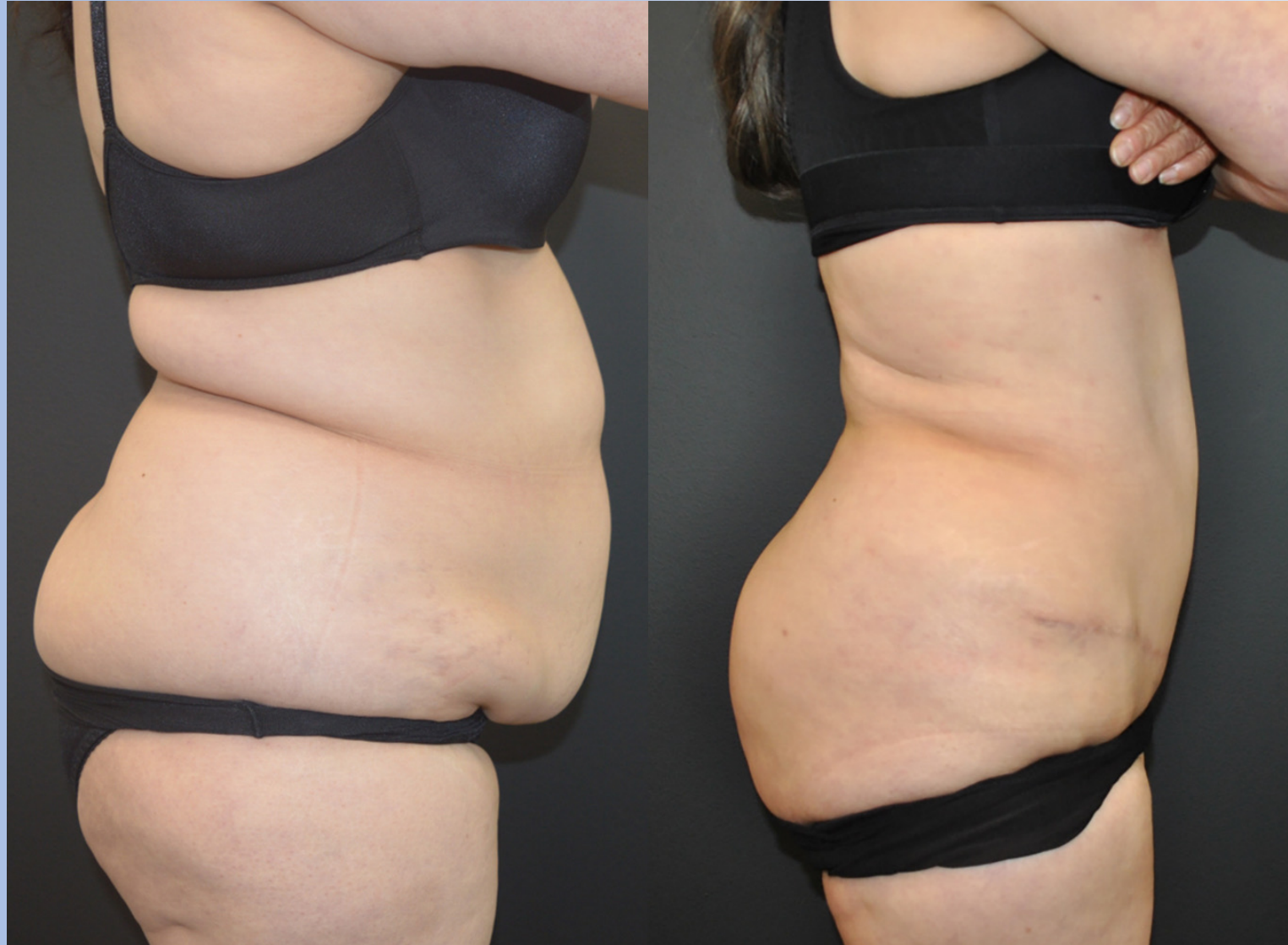Stage 1, Option B: Panniculectomy



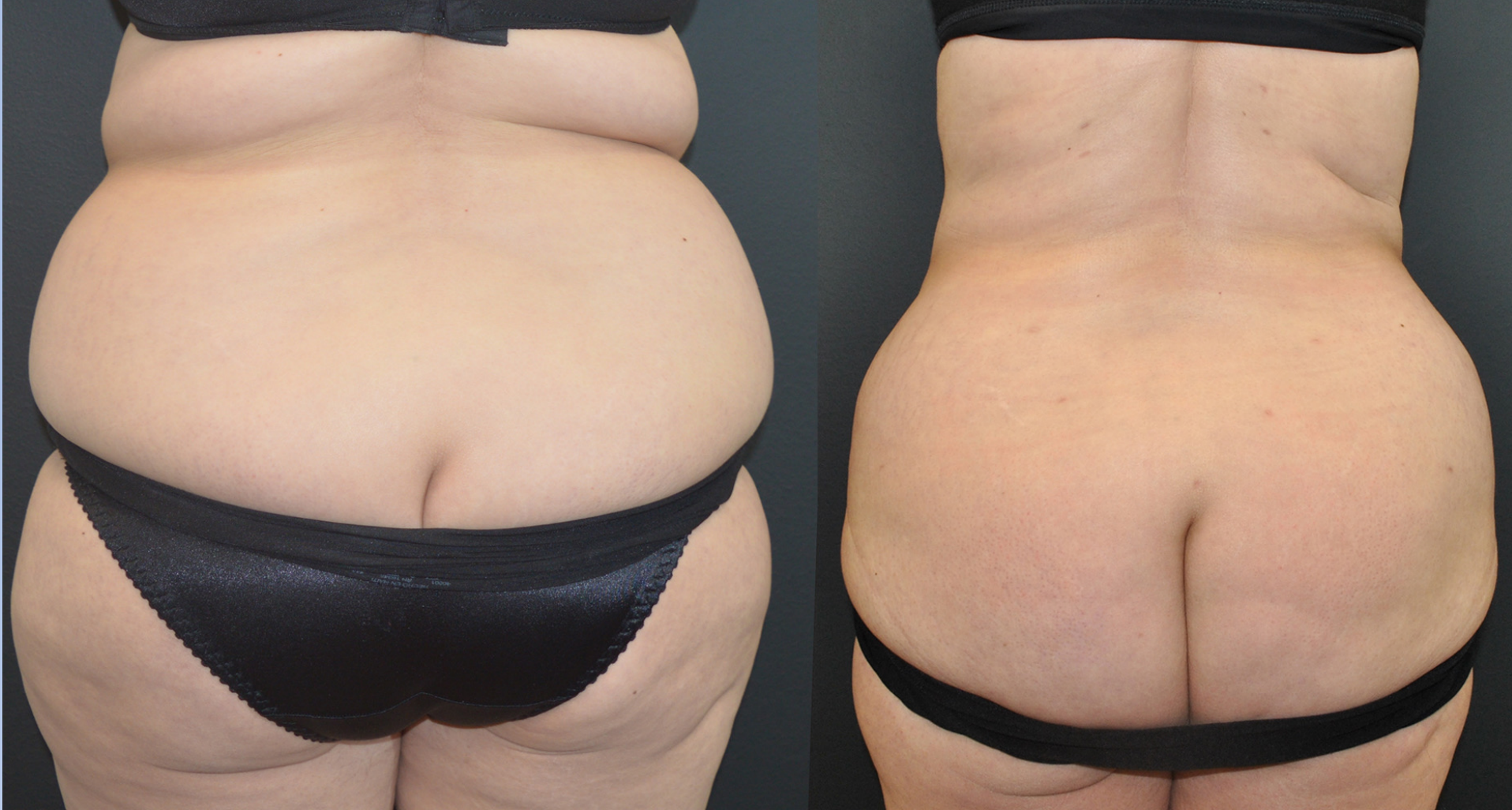Stage 1, Matarasso Type IV Abdominoplasty with Upper Abdominal and Posterior Liposuction



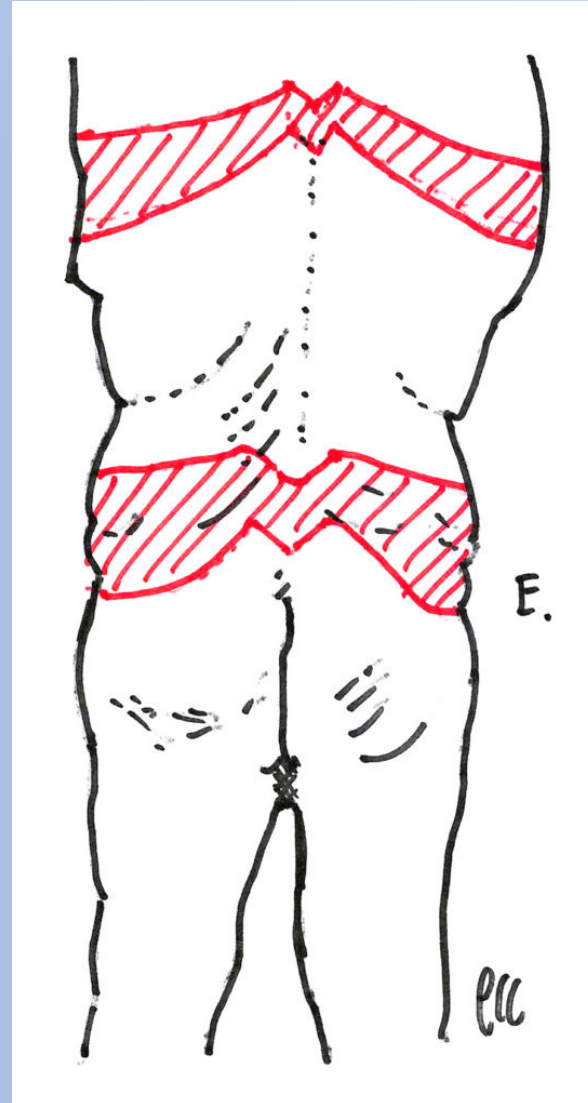
58 yo 8 months after abdominoplasty; SAL of upper abdomen and bilateral hips, flanks, and back, 5 mo after flanks, sides of breasts and fat injections to buttocks, bodytite to flanks. 20 lb weight loss.



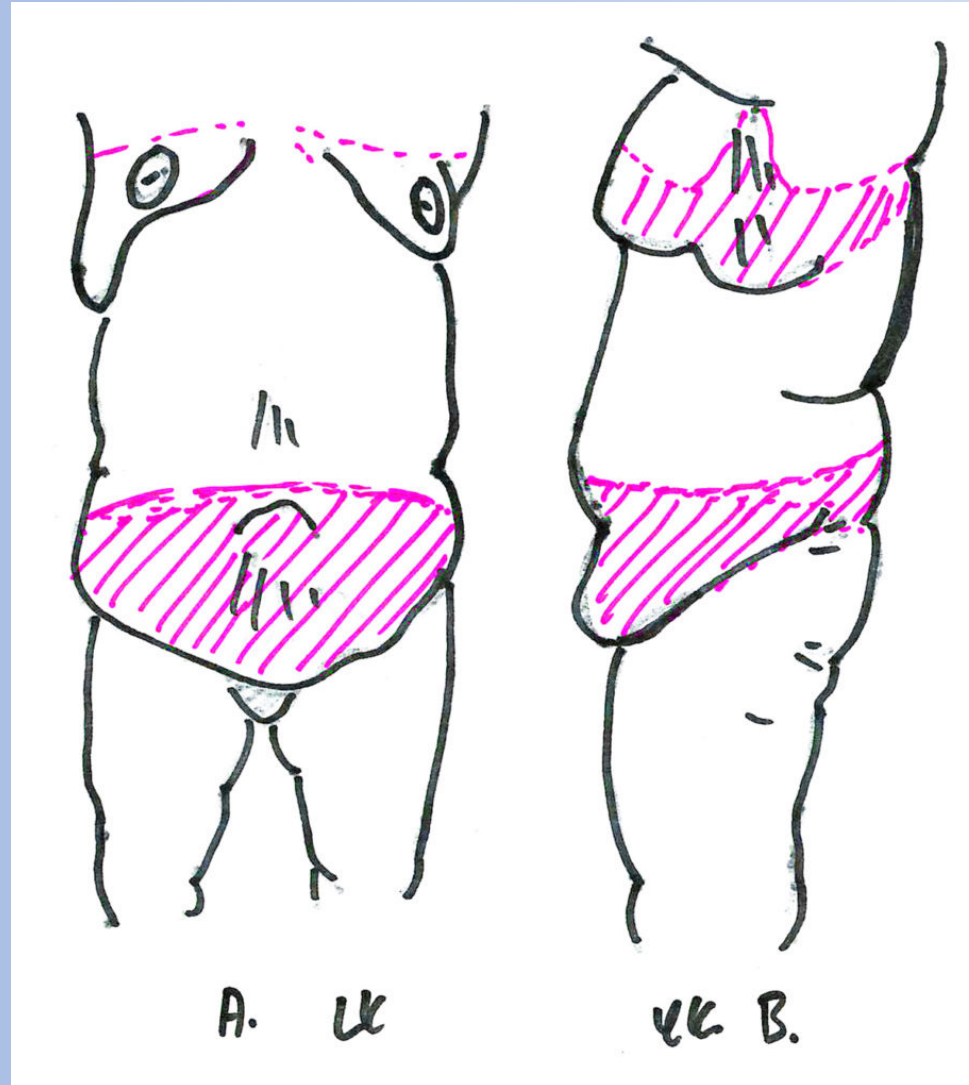
58 year-old f., 5'0" 150 lbs initially. BMI 29.3 to 25.5 after surgery. 8 months after abdominoplasty; Liposuction of upper abdomen and bilateral hips, flanks, and back, 5 months after flanks, sides of breasts and fat injections to buttocks, Bodytite to flanks. 20 lb weight loss. Initial surgery: 1250 ml aspirate / 1541 gm excision lower abdomen



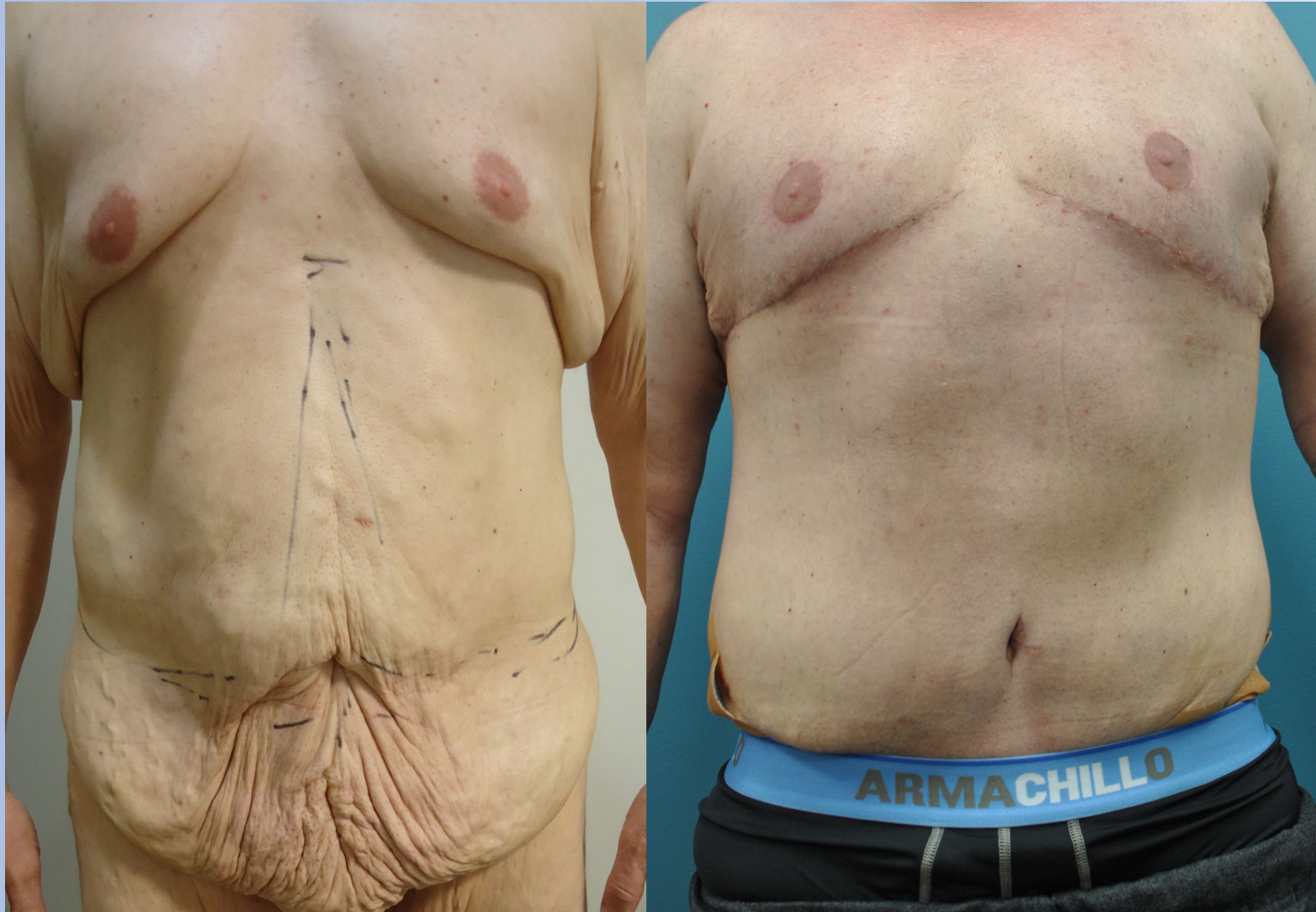
Stage 1



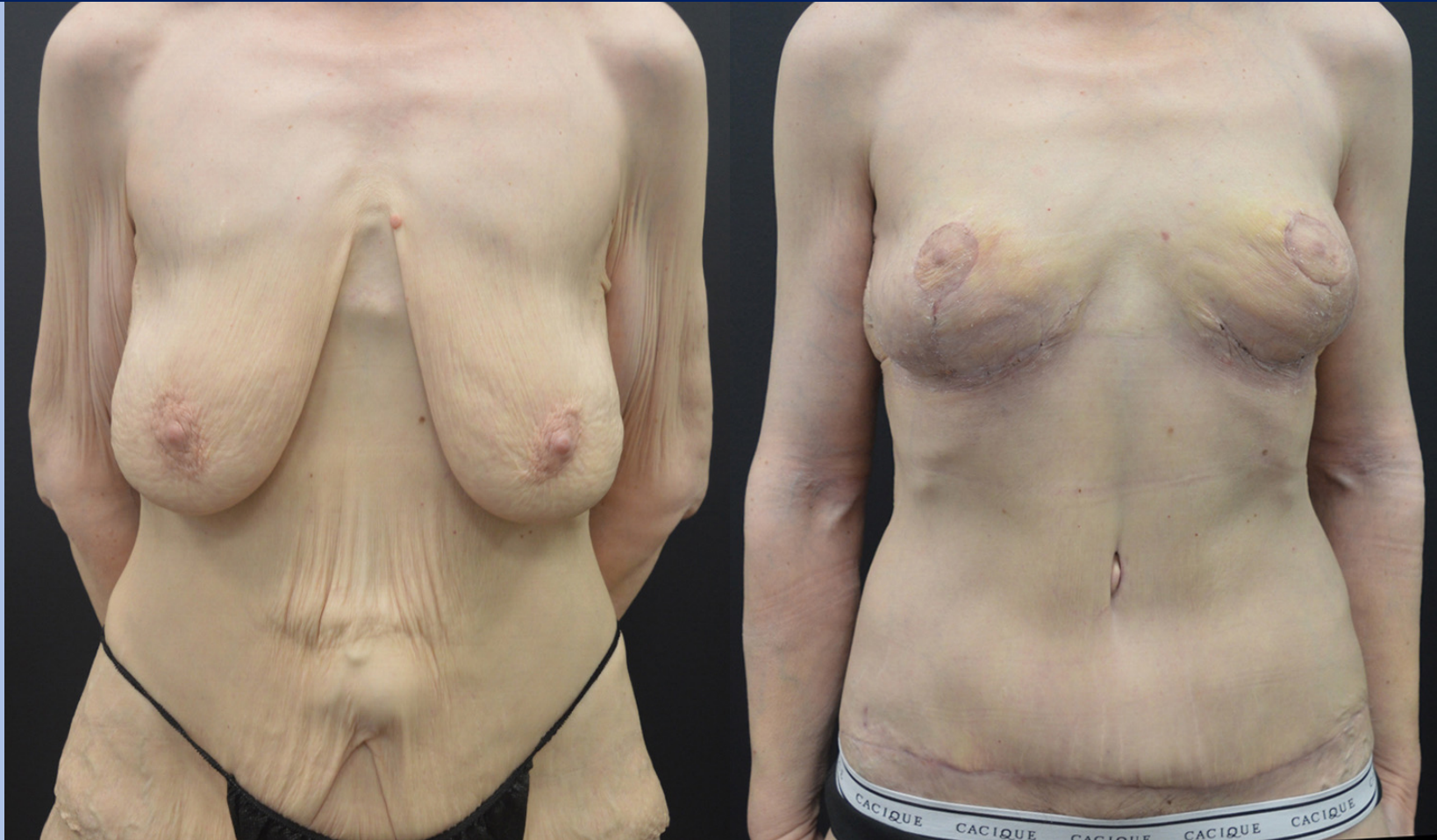
Stage 1



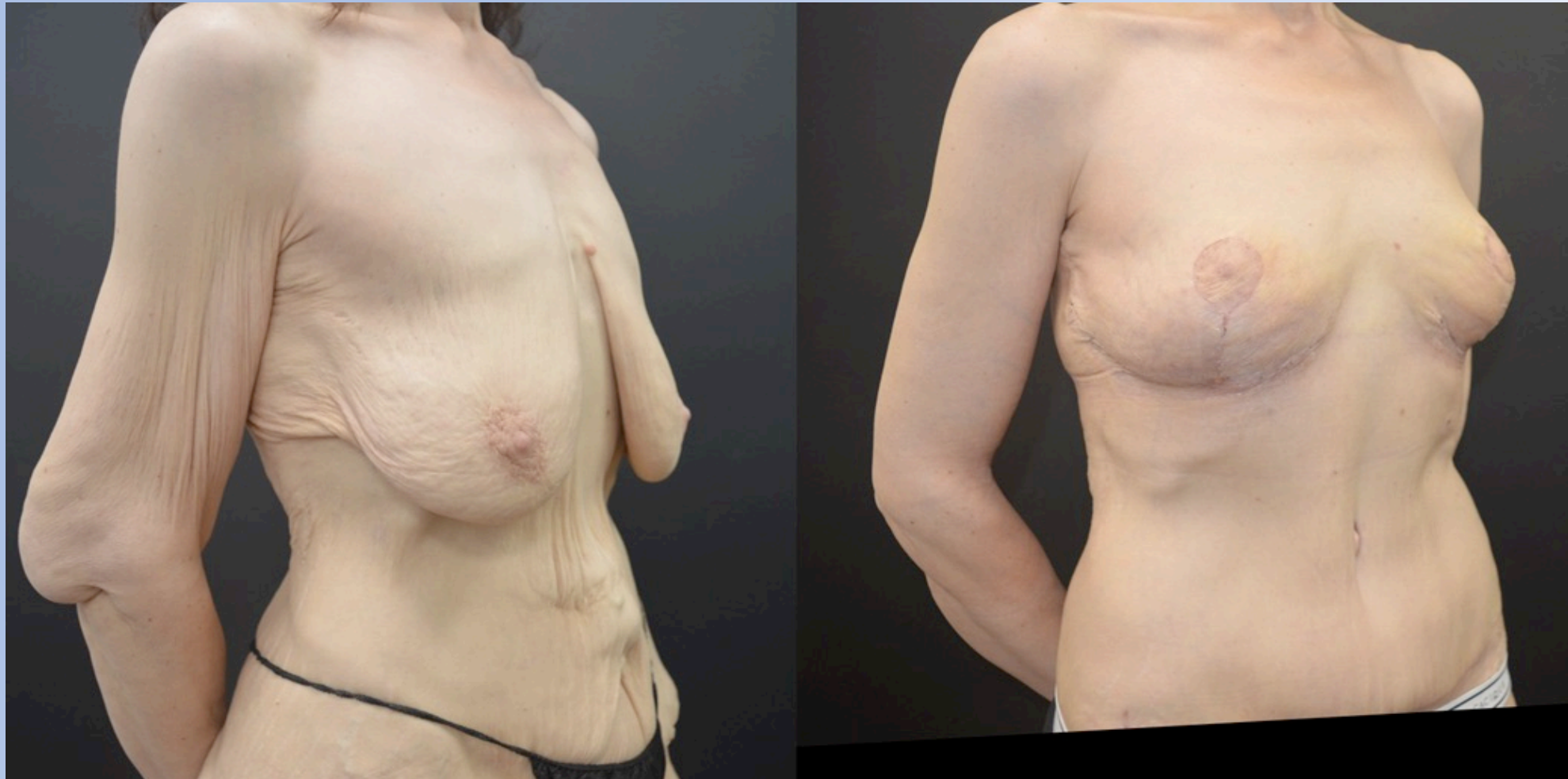Stage 1 & 2 A & 2B



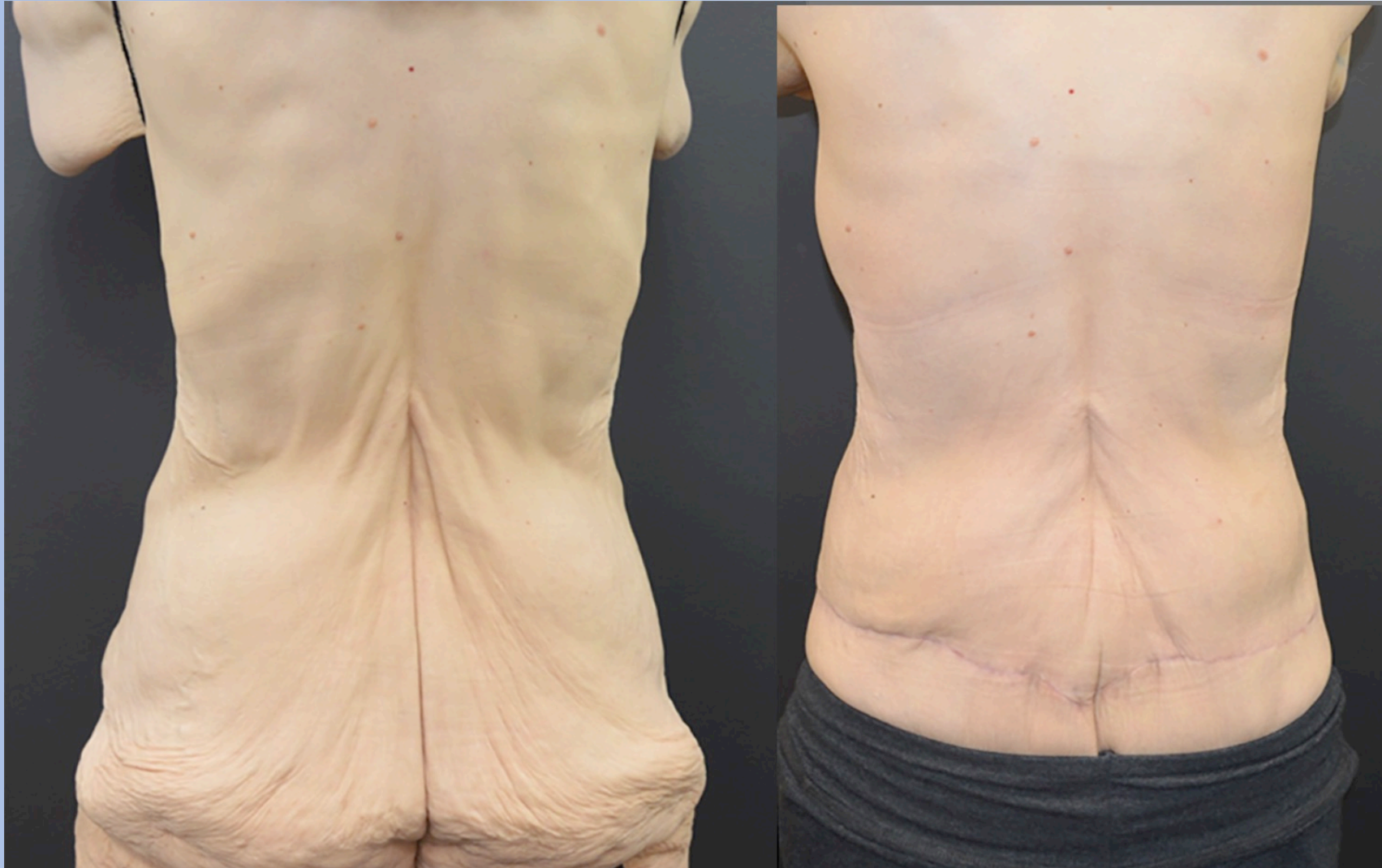Stage 1. 56-year-old female before and after bcs: lower body lift, abdominoplasty, breast lift and brachioplasty



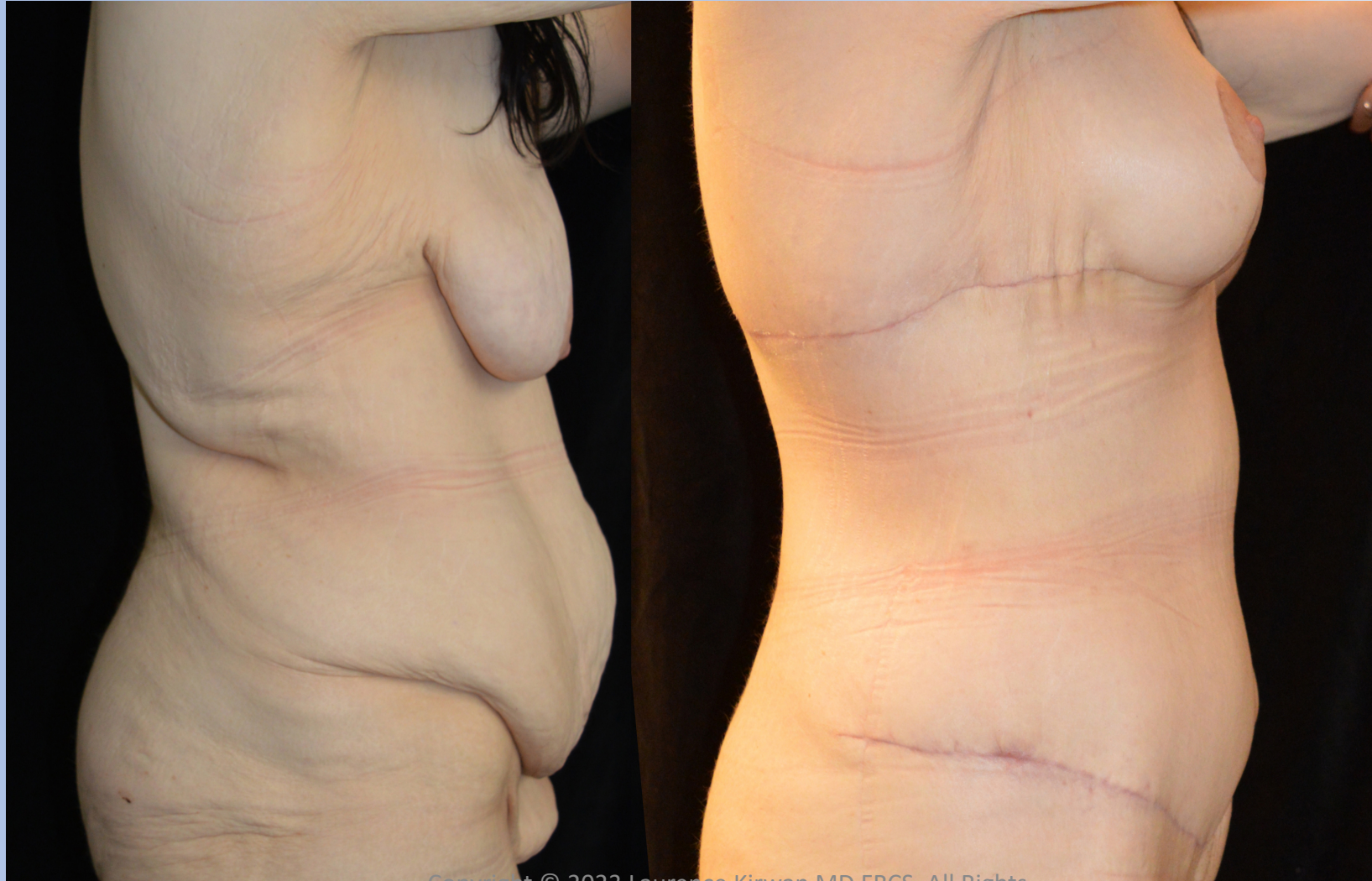Stage 1



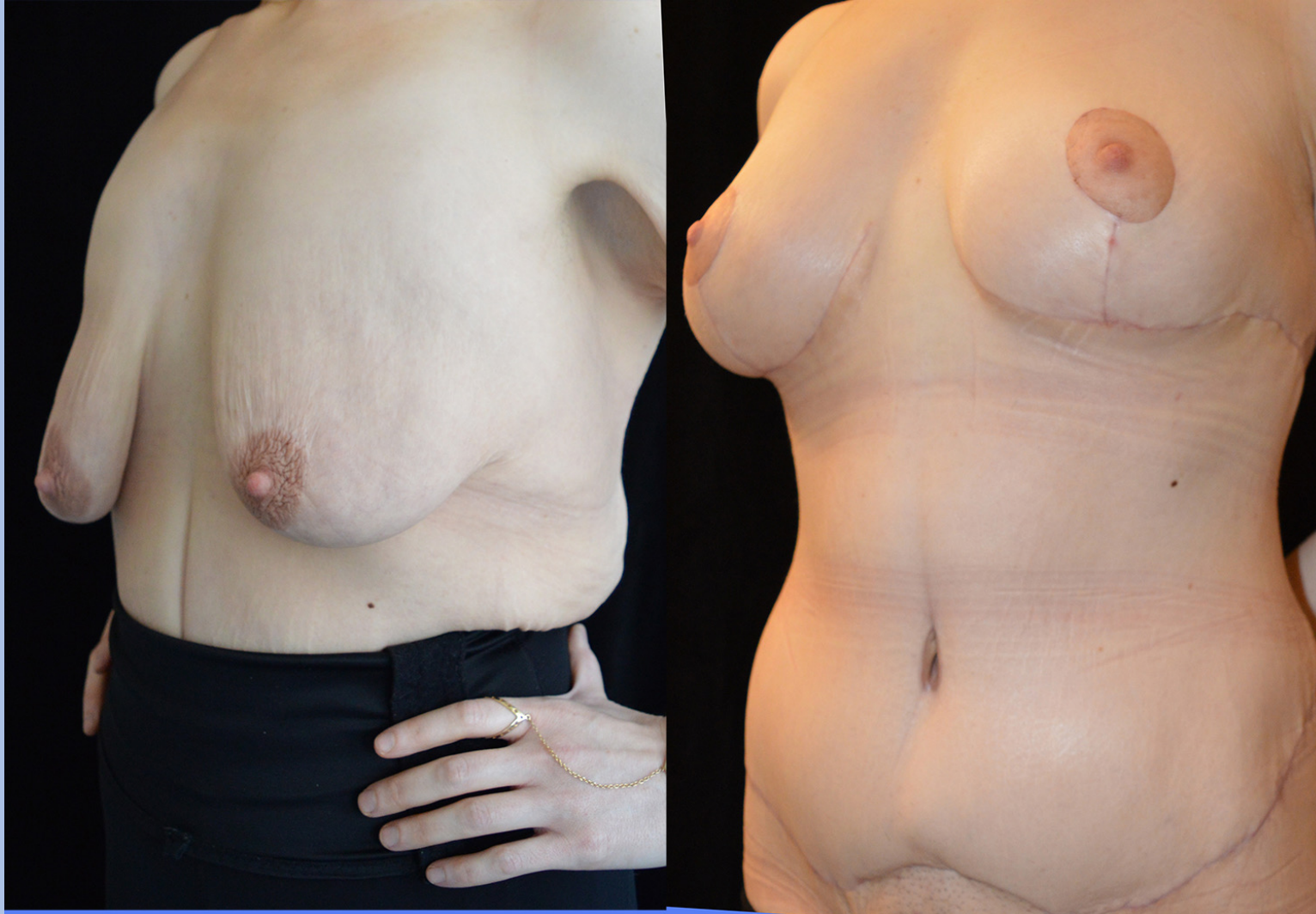Stage 1



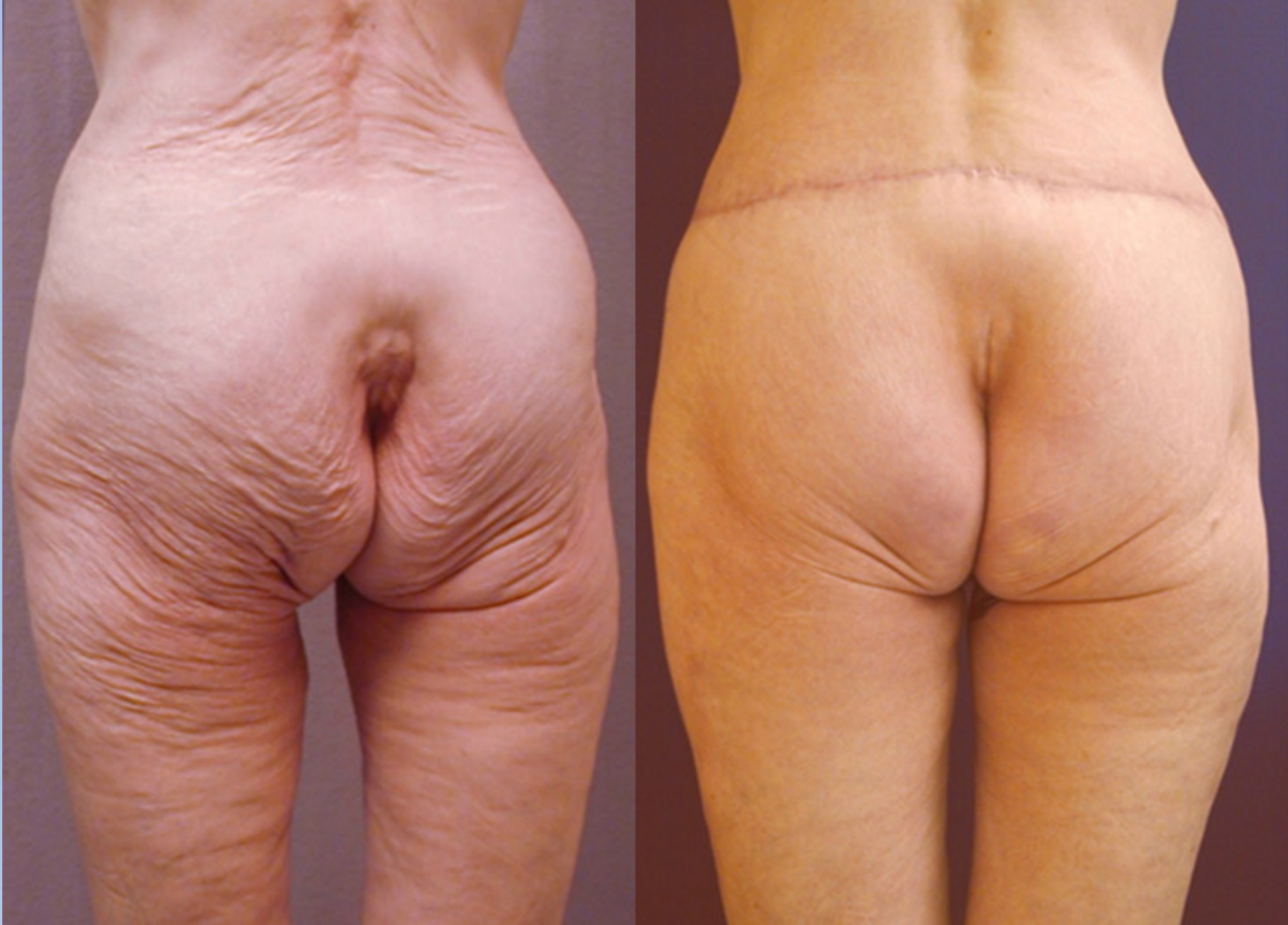34-YEAR-OLD FEMALE BEFORE AND AFTER BCS: EXTENDED, ABDOMINOPLASTY, BREAST LIFT AND UPPER BODY LIFT



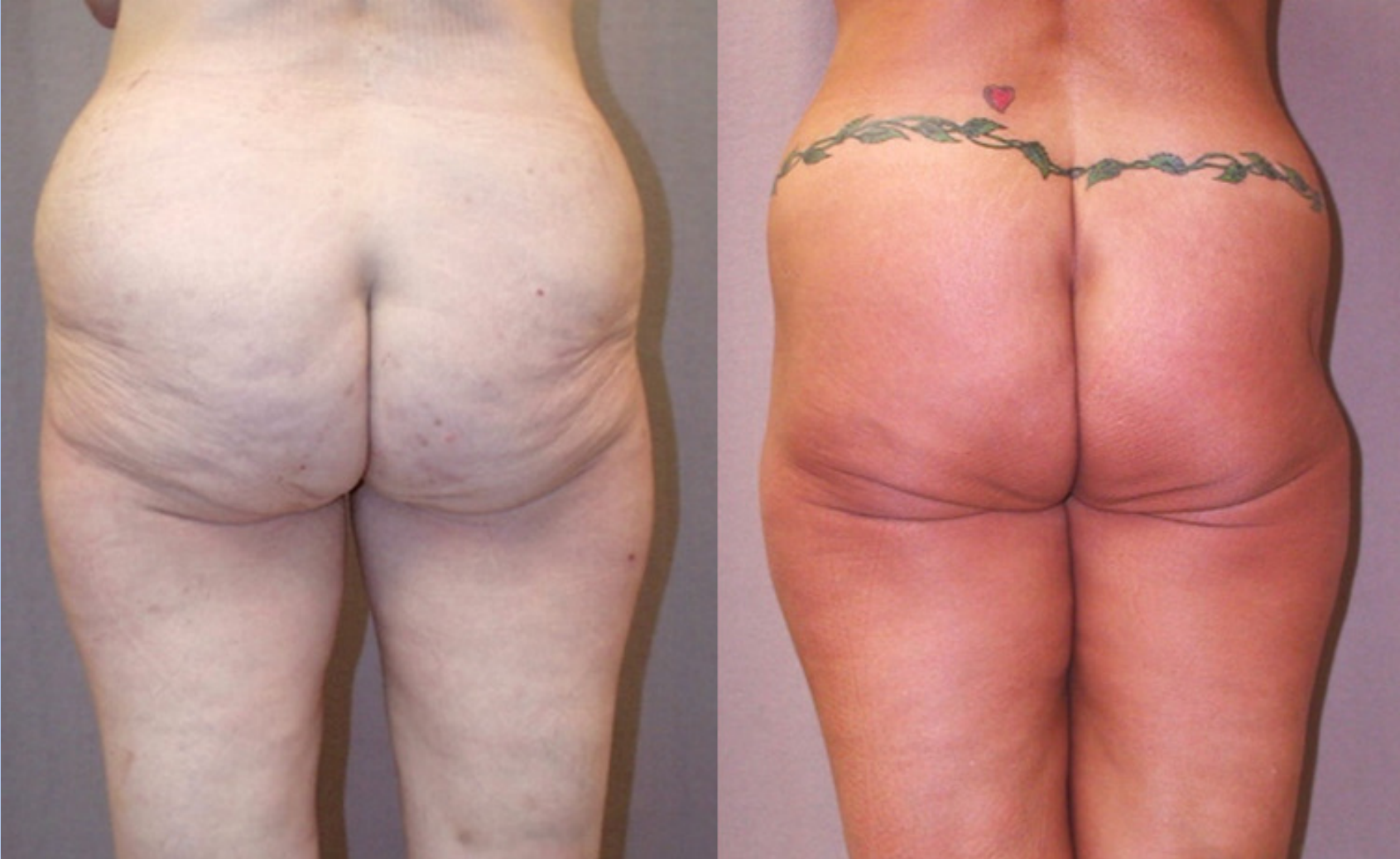34-YEAR-OLD FEMALE BEFORE AND AFTER BCS: EXTENDED, ABDOMINOPLASTY, BREAST LIFT AND UPPER BODY LIFT



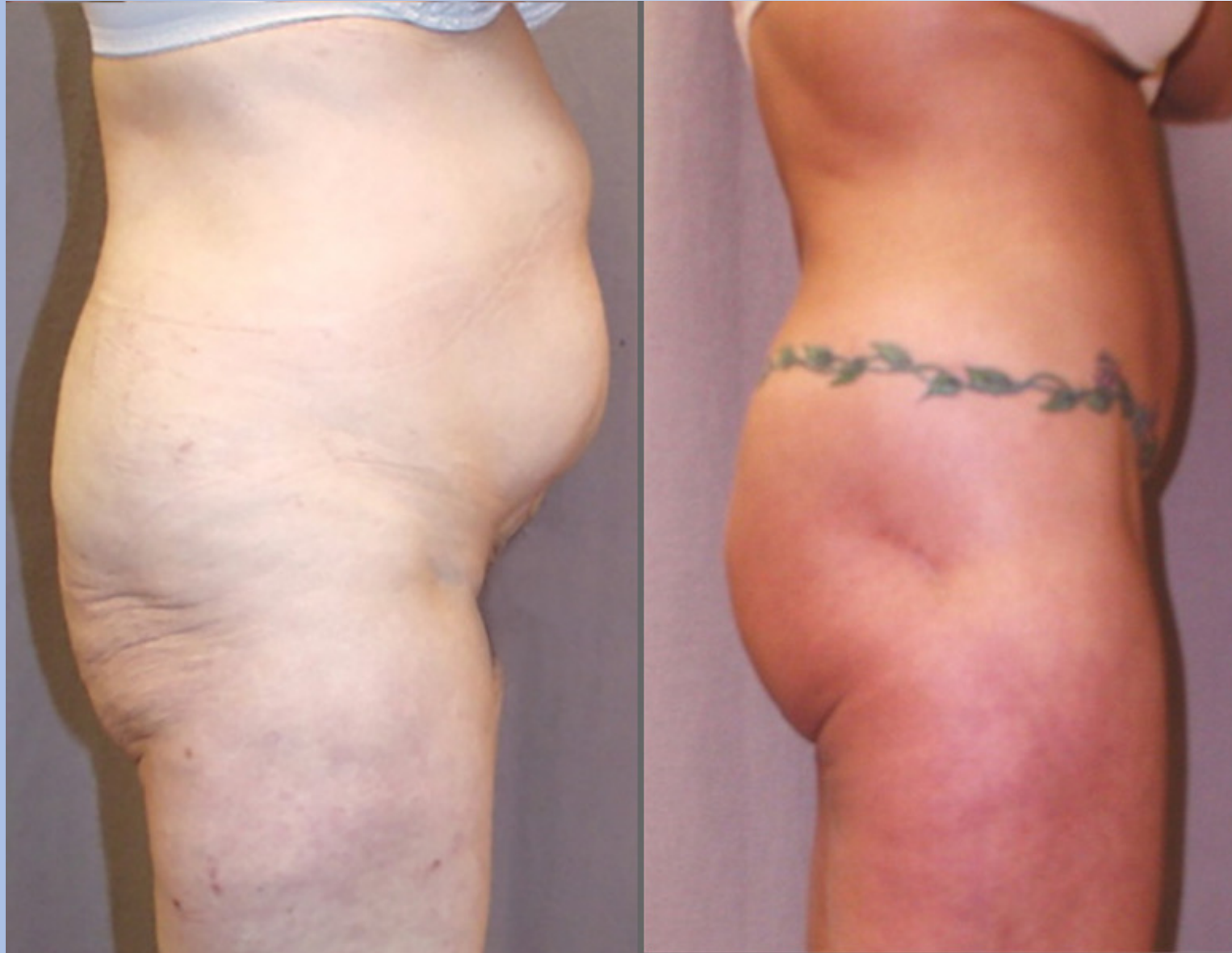Stage 1 Lower Body Lift without Abdominoplasty



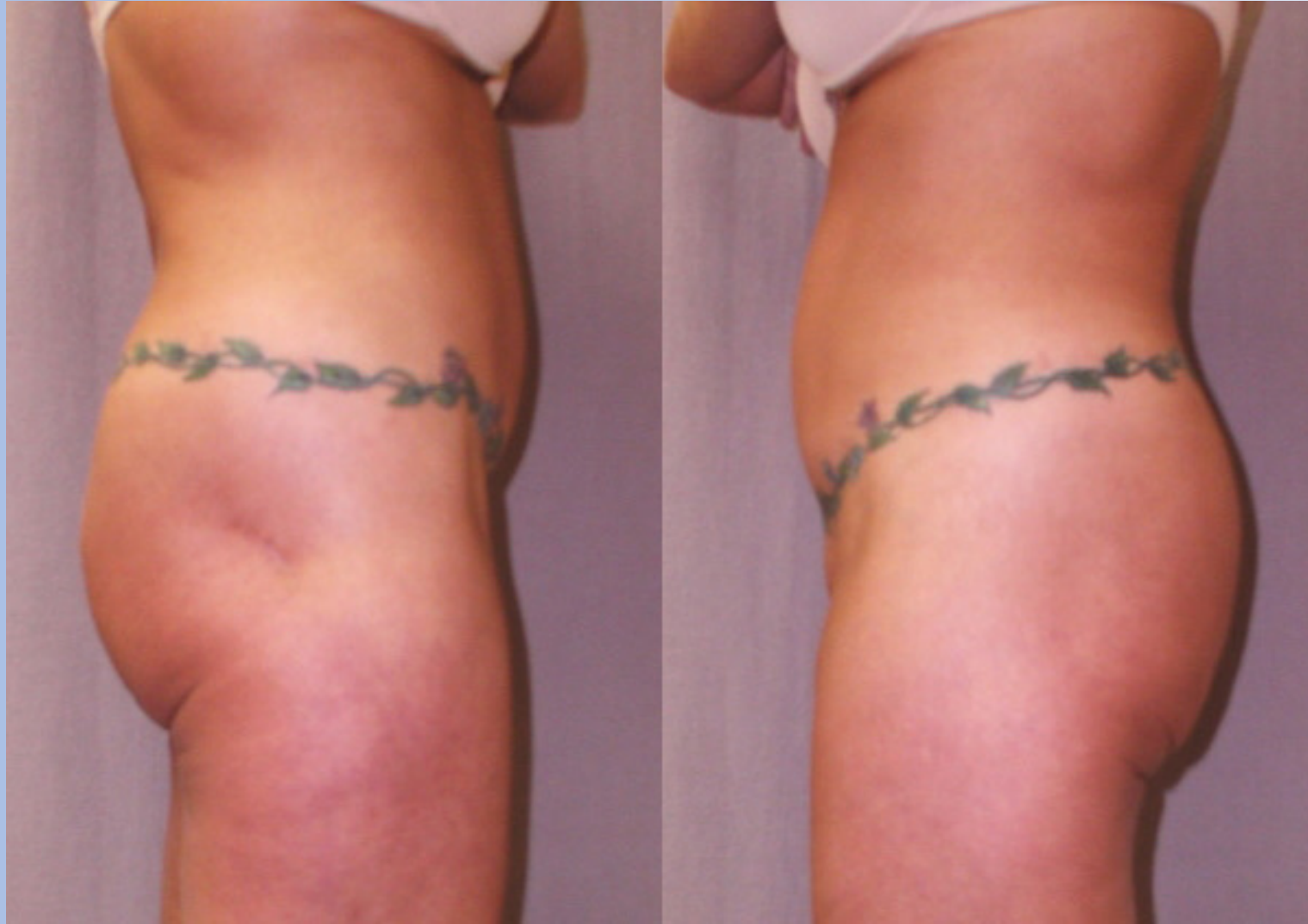Stage 1 Lower Body Lift with Abdominoplasty



Stage 1 Lower Body Lift with Abdominoplasty



Stage 1 Lower Body Lift with Abdominoplasty



**Stage
1**

LOWER BODY

**Stage
2A**

UPPER BODY

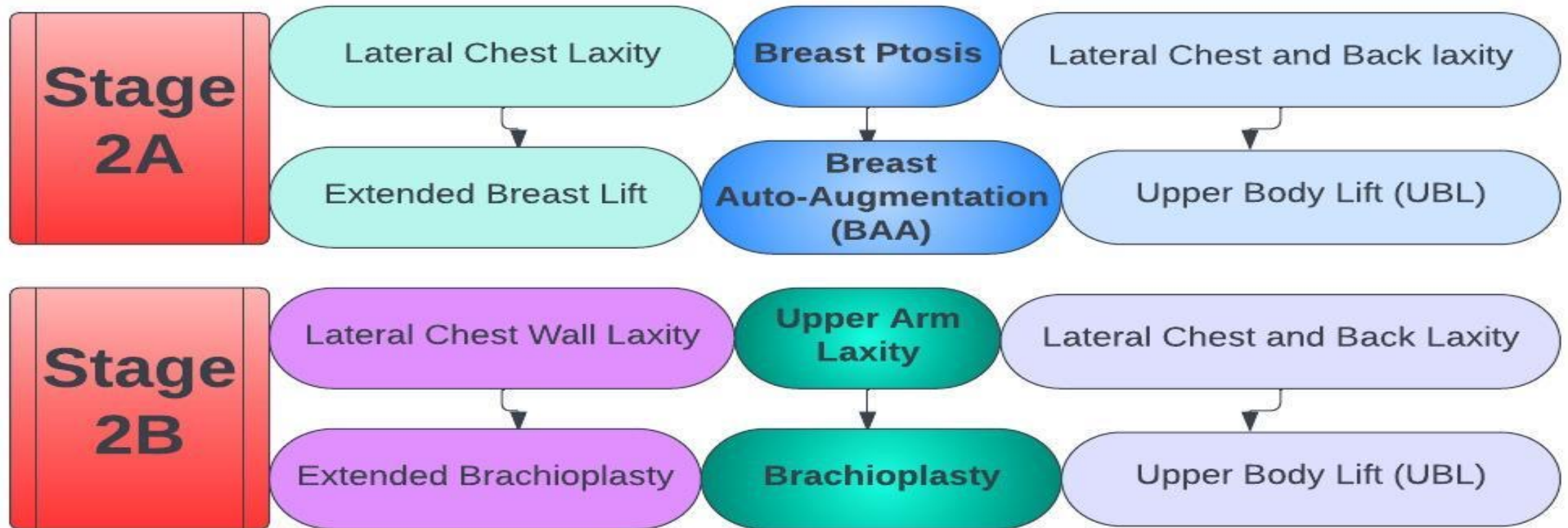
**Stage
2B**

UPPER EXTREMITY

**Stage
3**

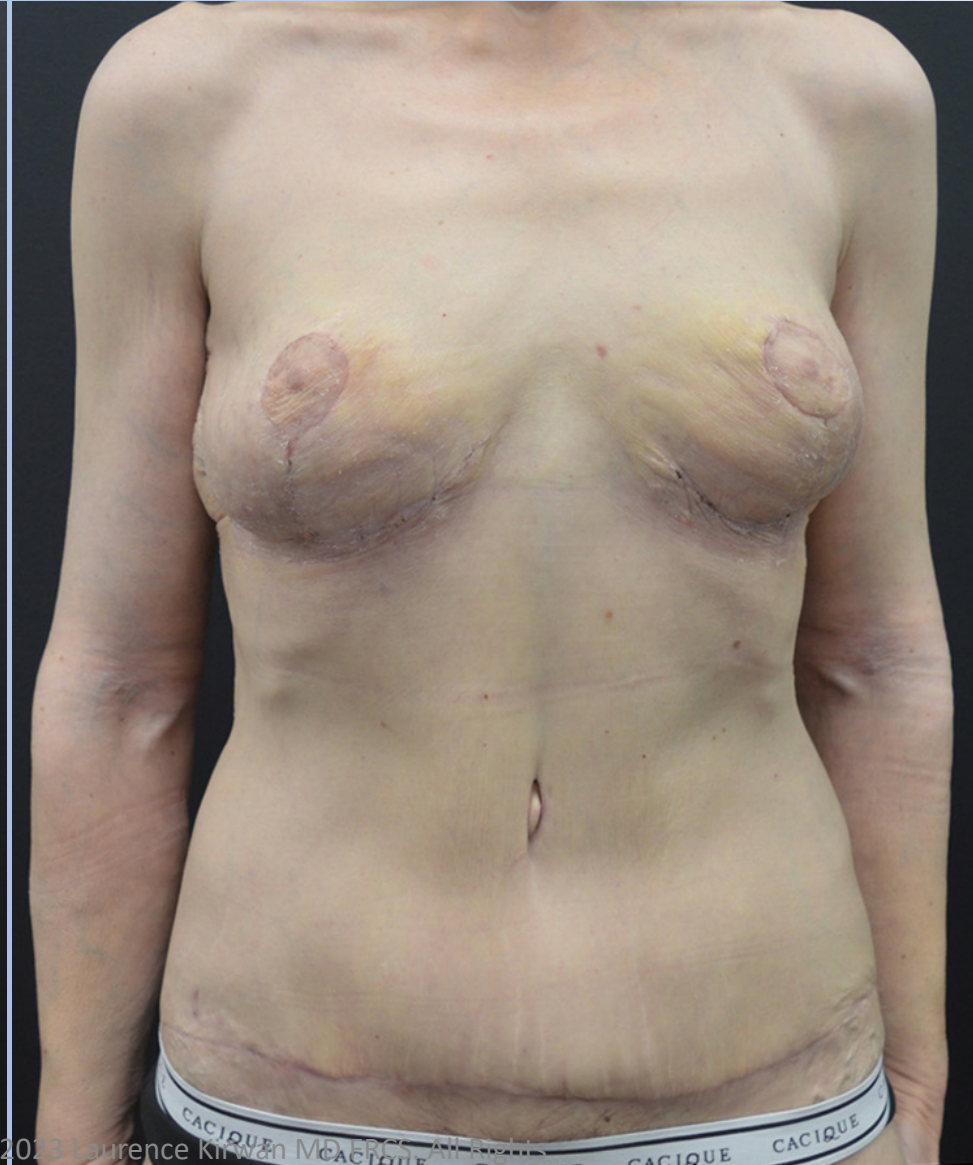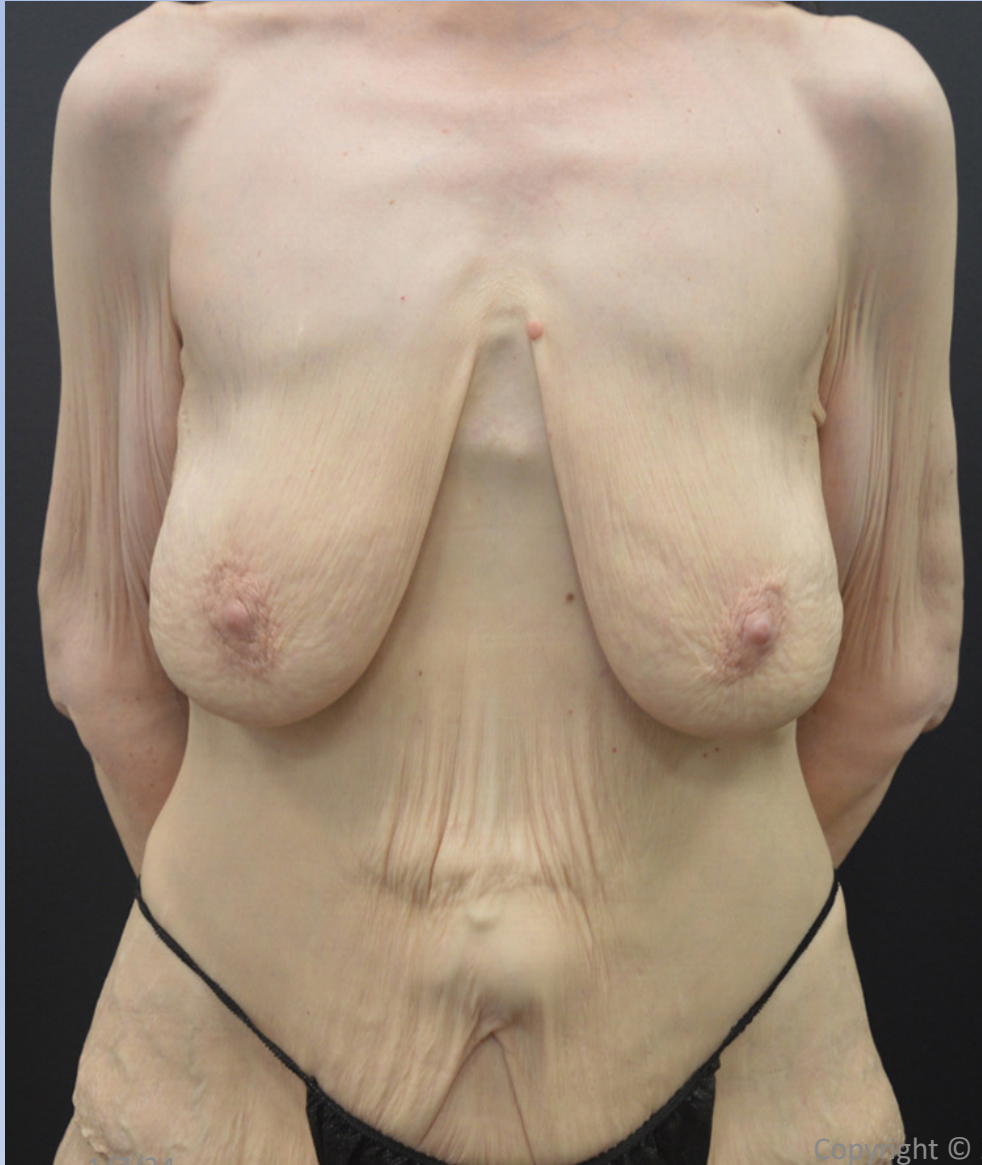
LOWER EXTREMITY

Female Stage 2



Stage 1, 2A & 2B

56-yo Female Before And After BCS: LBL, Abdominoplasty, BAA, Brachioplasty.

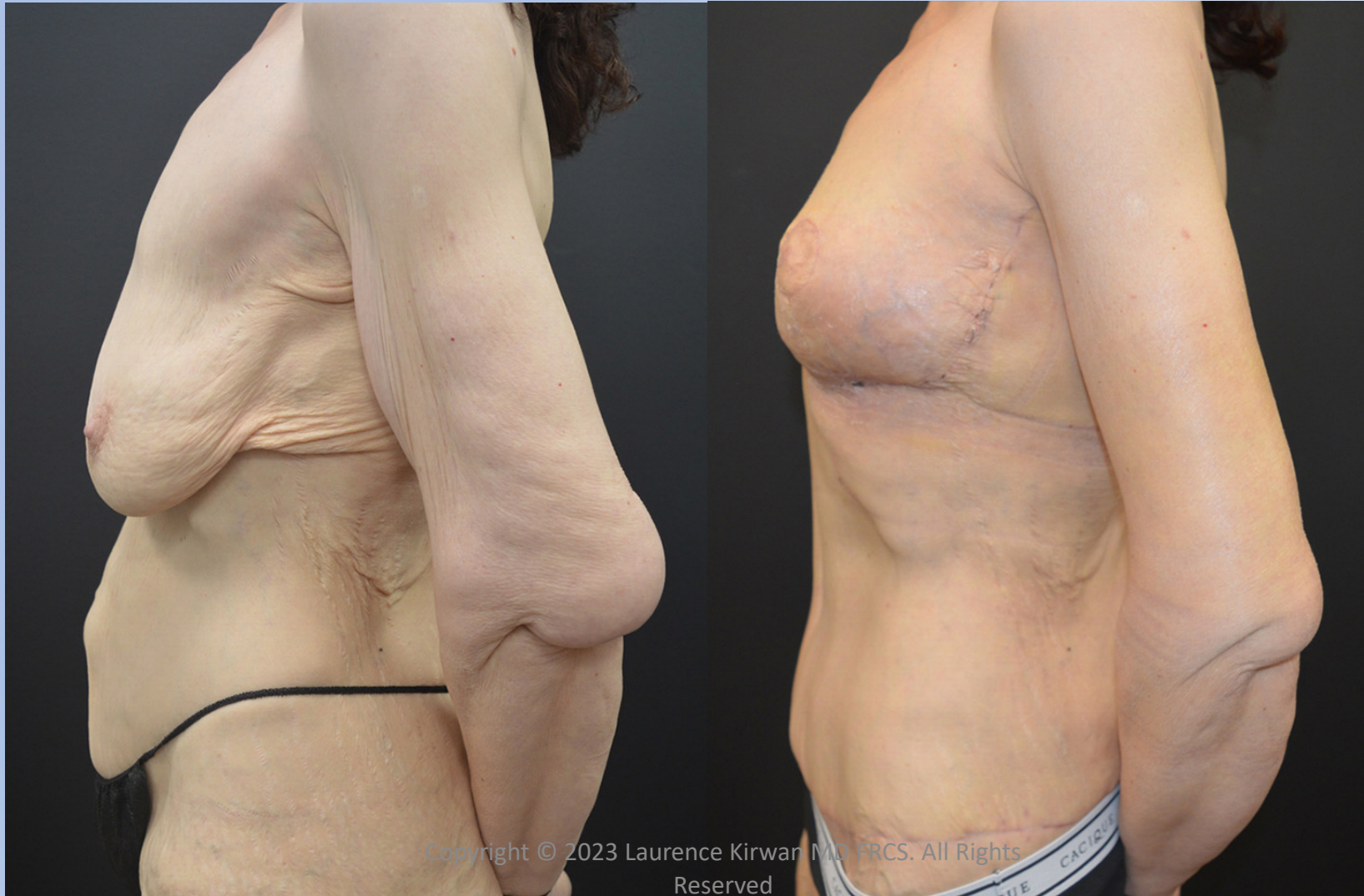

1/7/24

Copyright © 2023 Laurence Kirwan MD, FRCS. All Rights Reserved

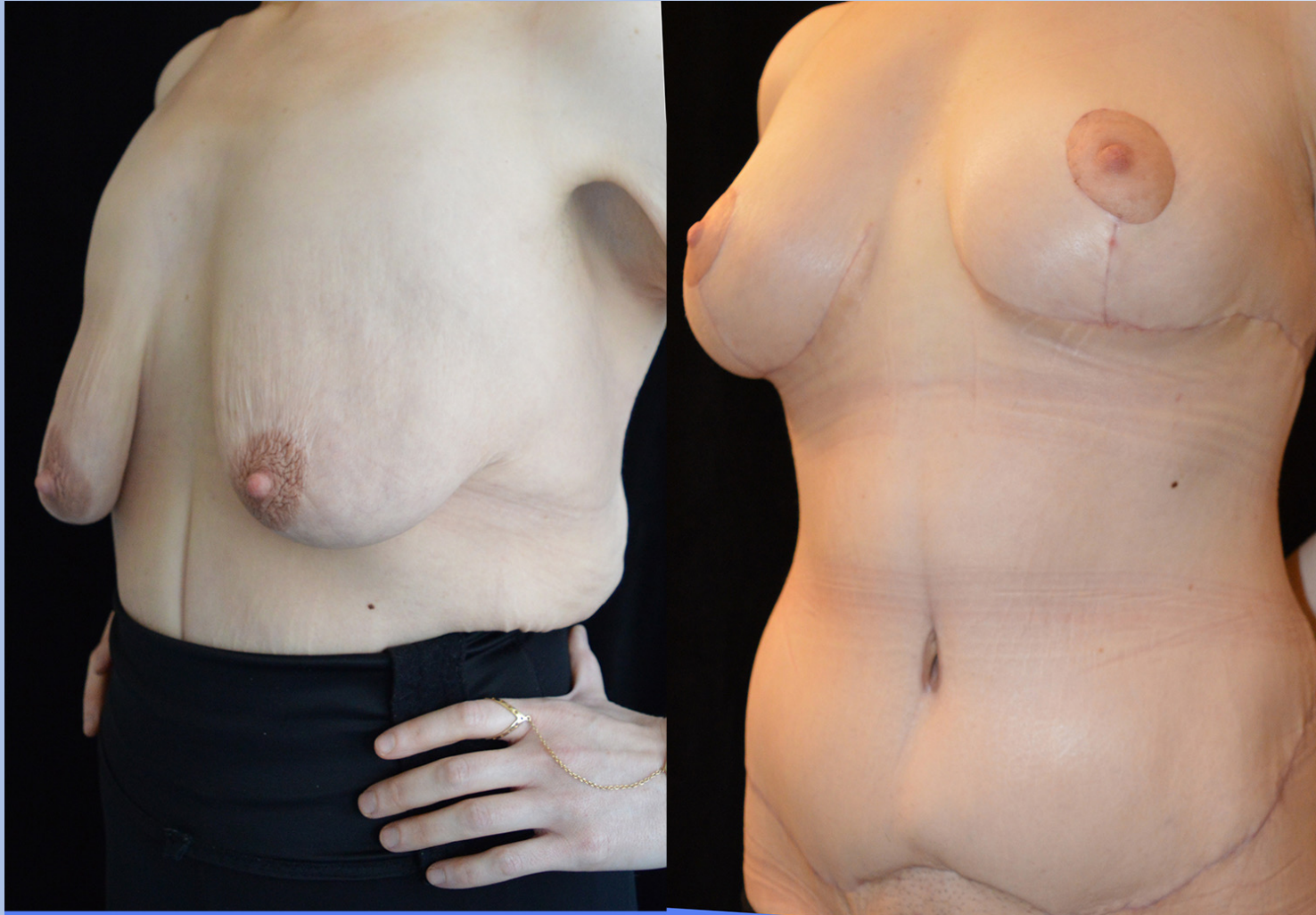
Stage 1, 2A & 2B

56-yo Female Before And After BCS: LBL, Abdominoplasty, BAA, Brachioplasty.

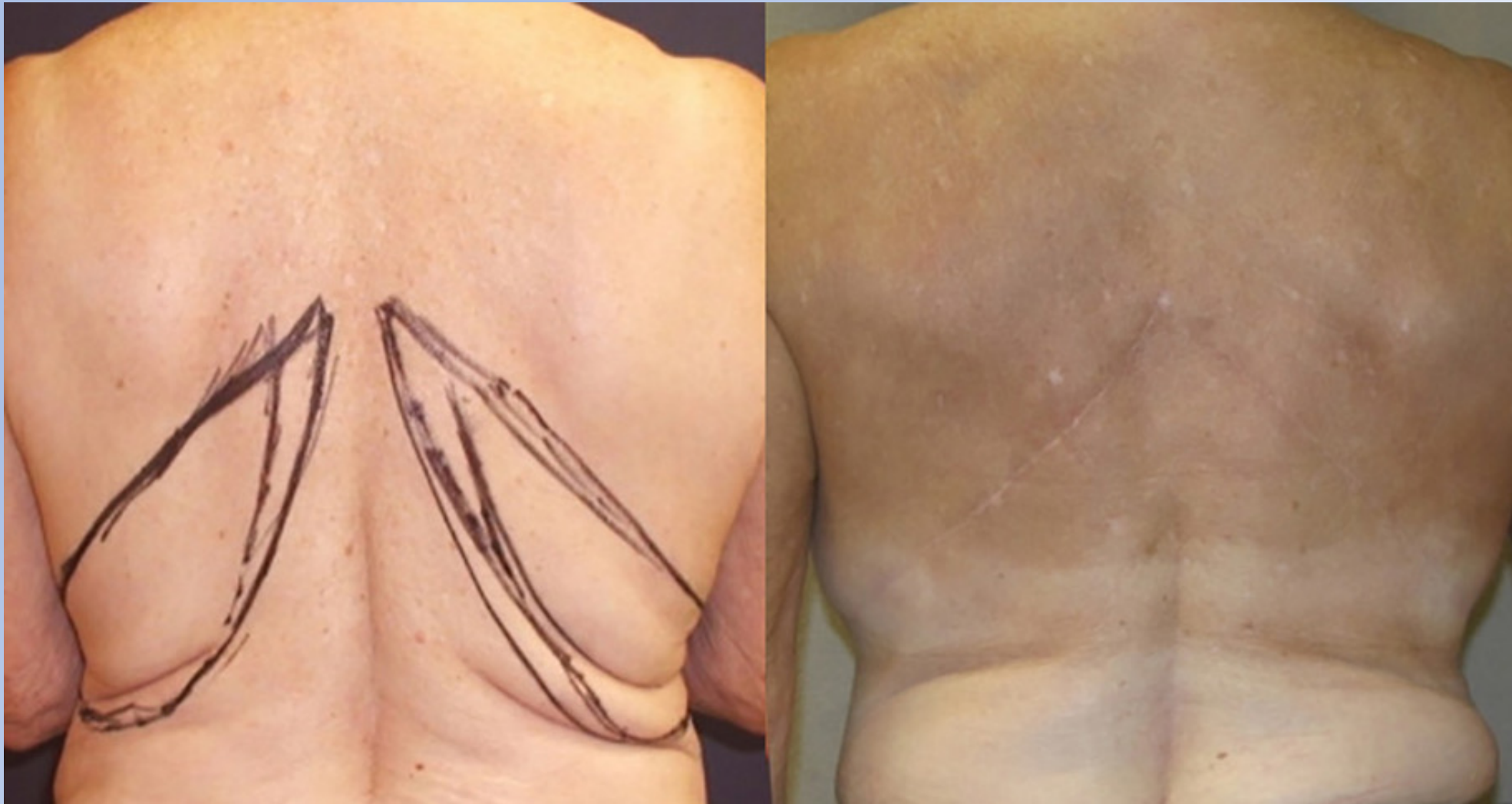

Stage 1, 2A

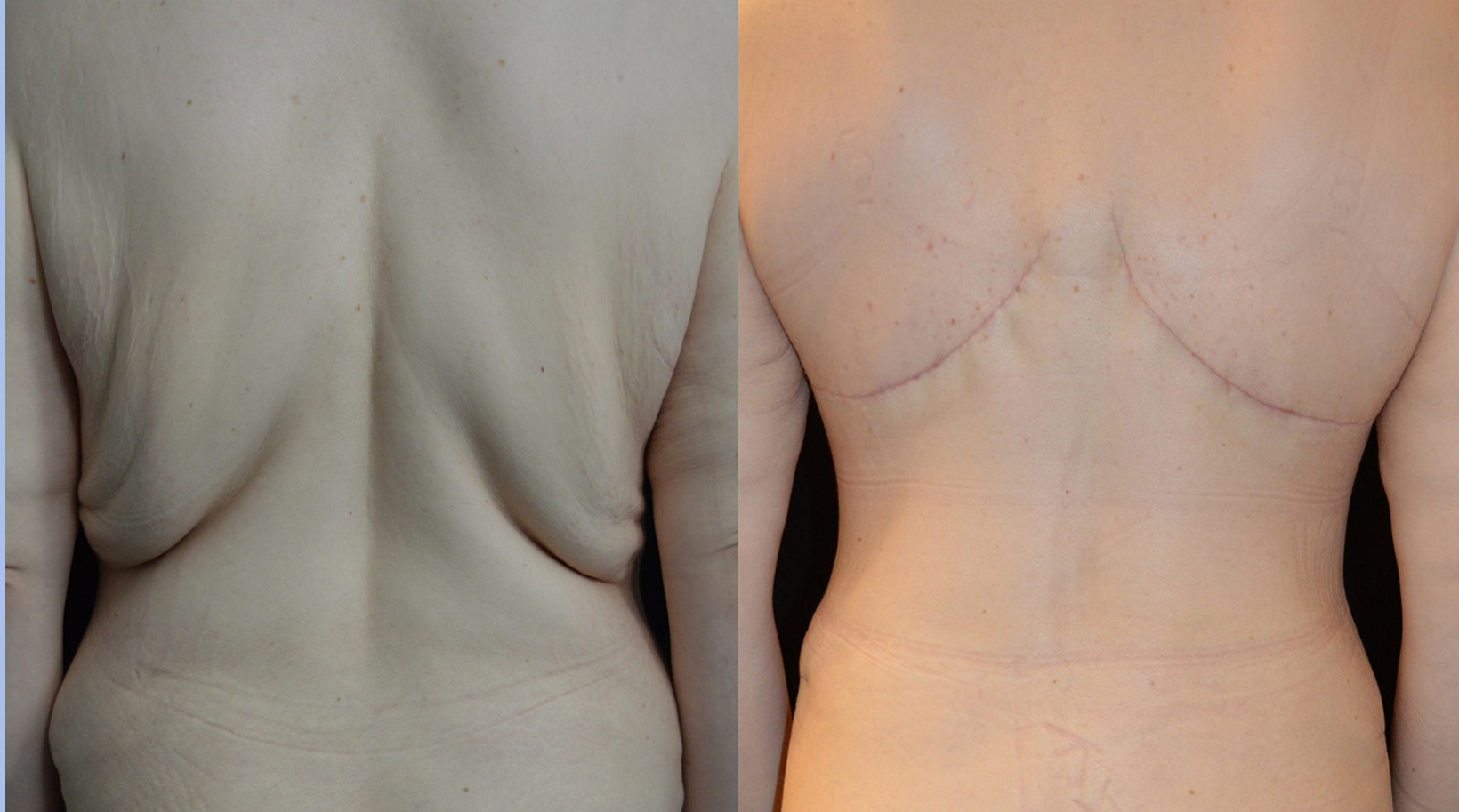34-year-old Female Extended Abdominoplasty, Breast Lift, Upper Body Lift



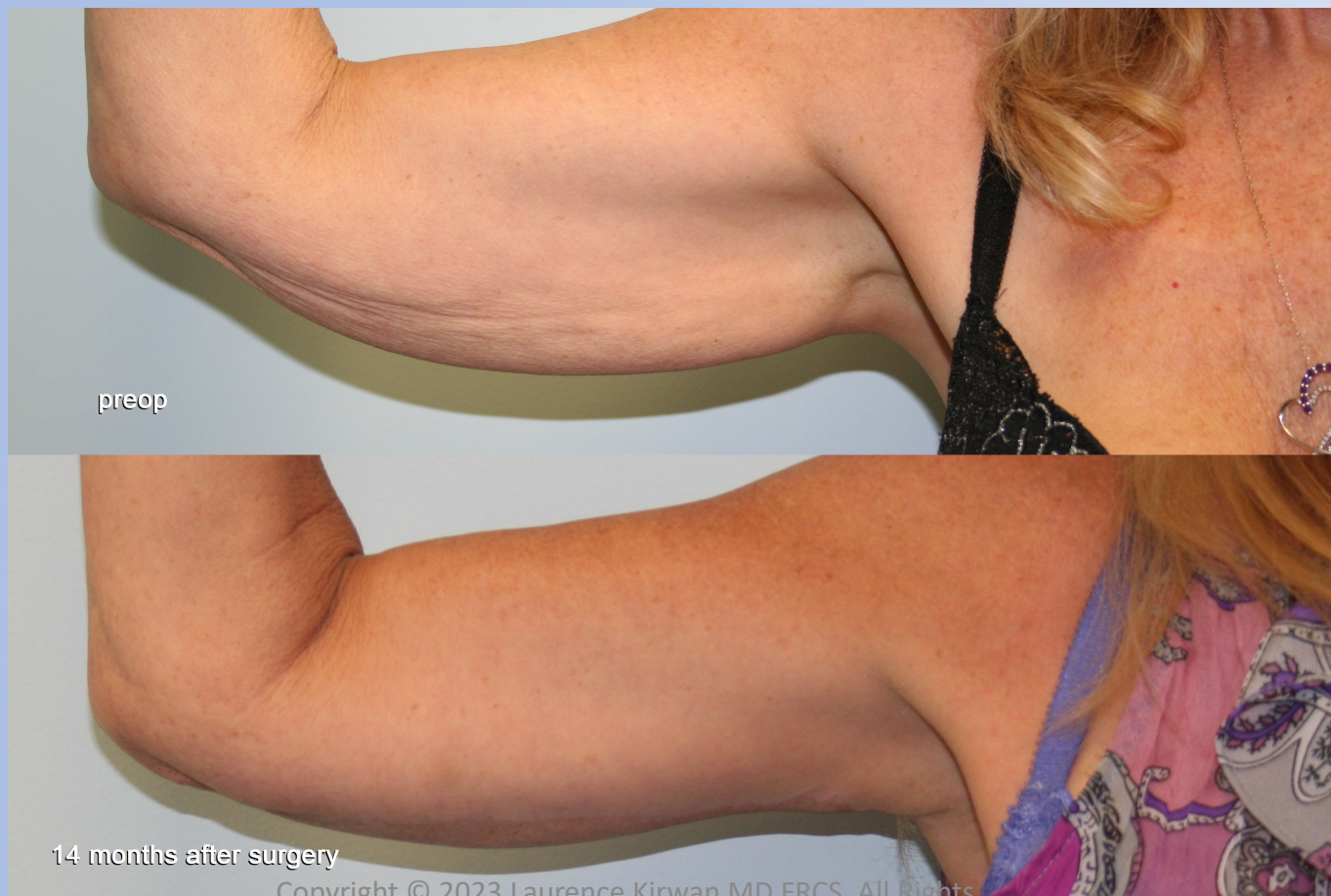Female Stage 2A, Flank Lift only



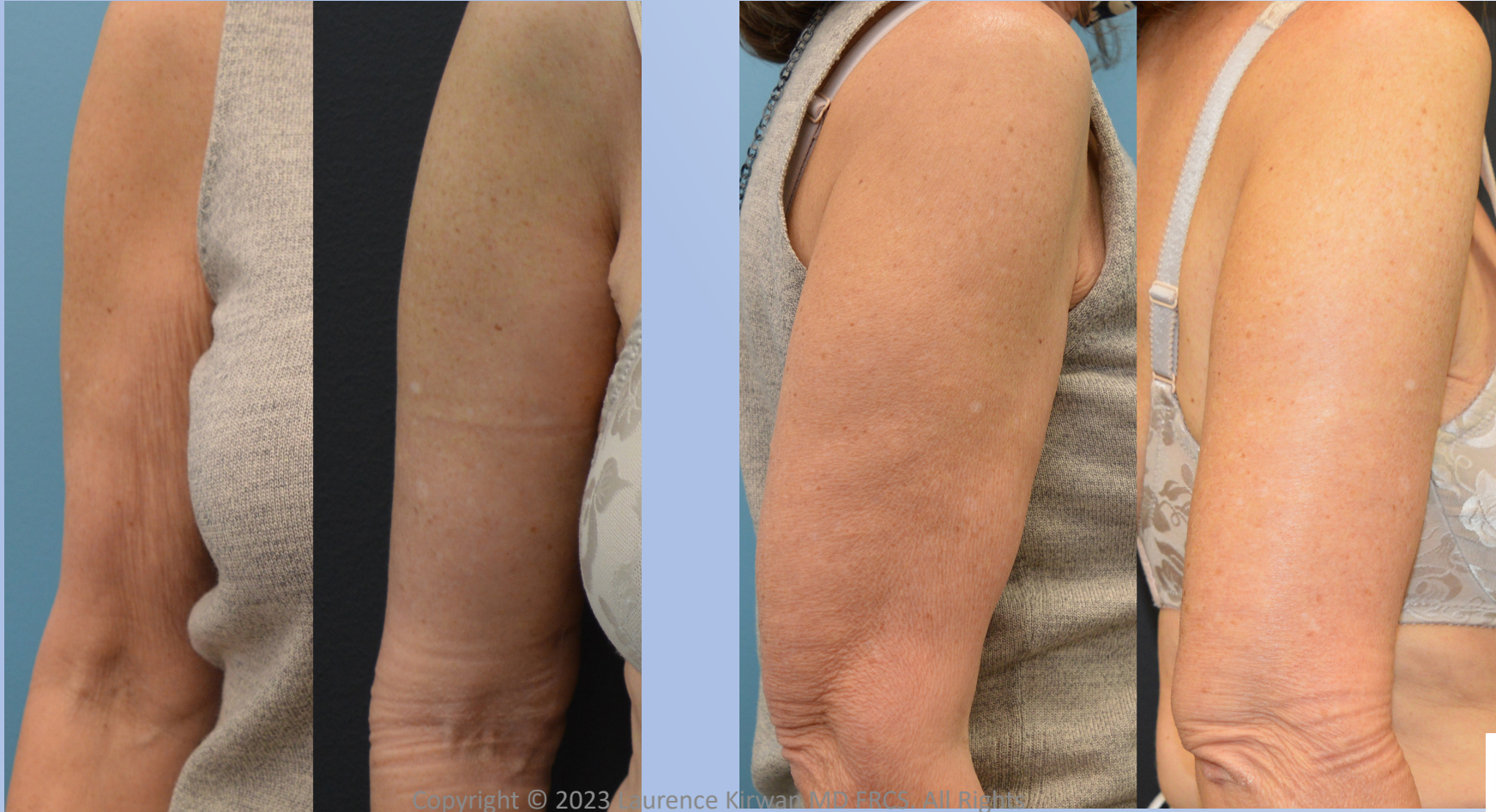Female Stage 2A, Flank Lift only



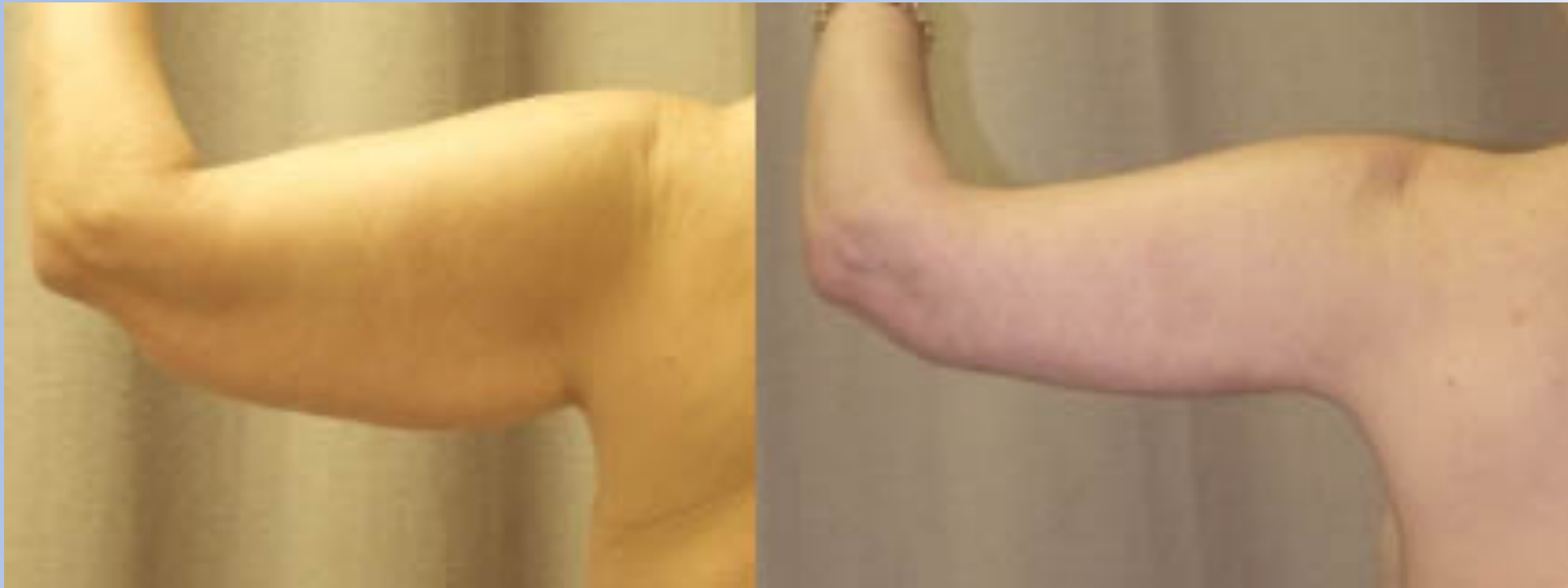Female Stage 2B - Brachioplasty



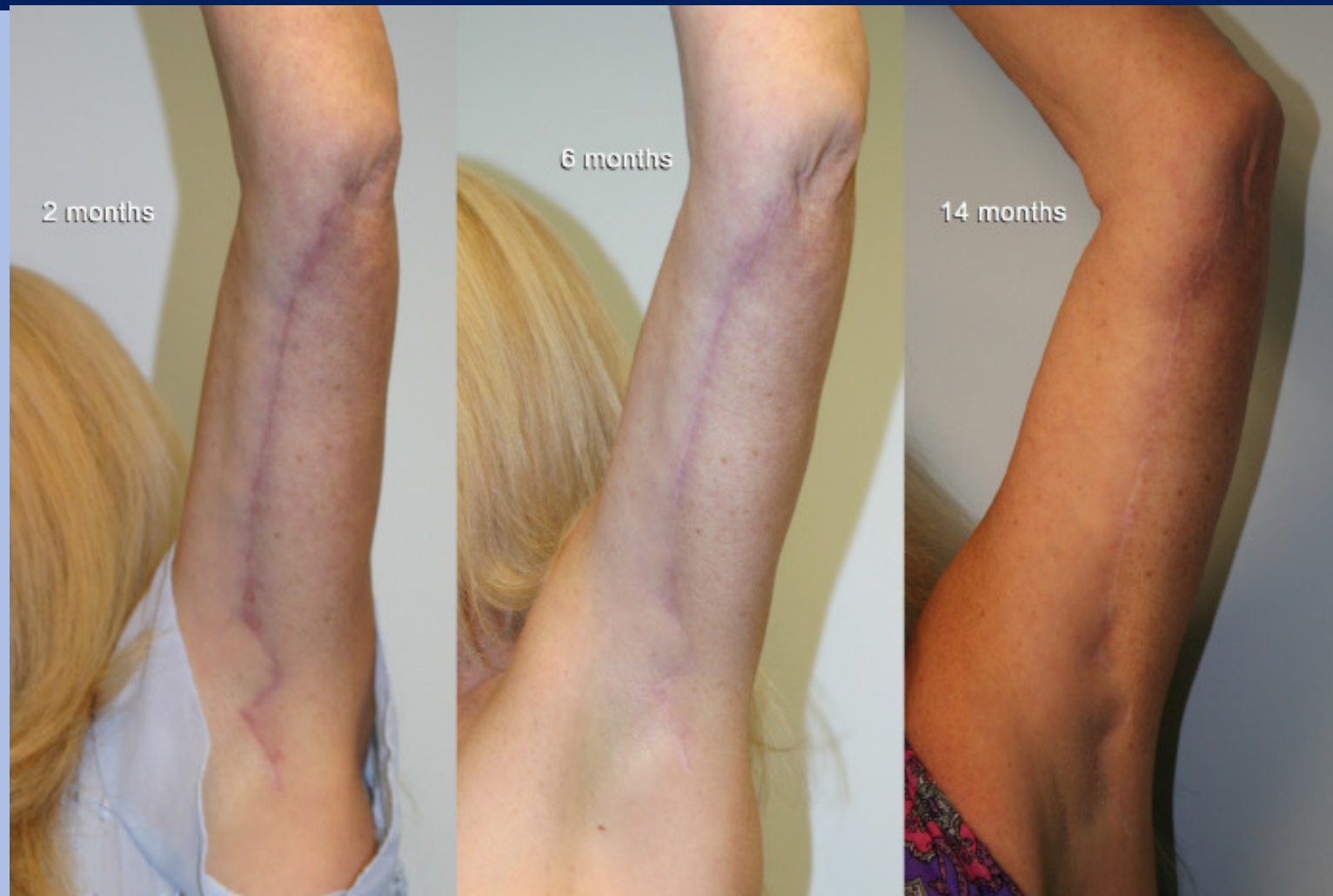Female Stage 2B - Brachioplasty



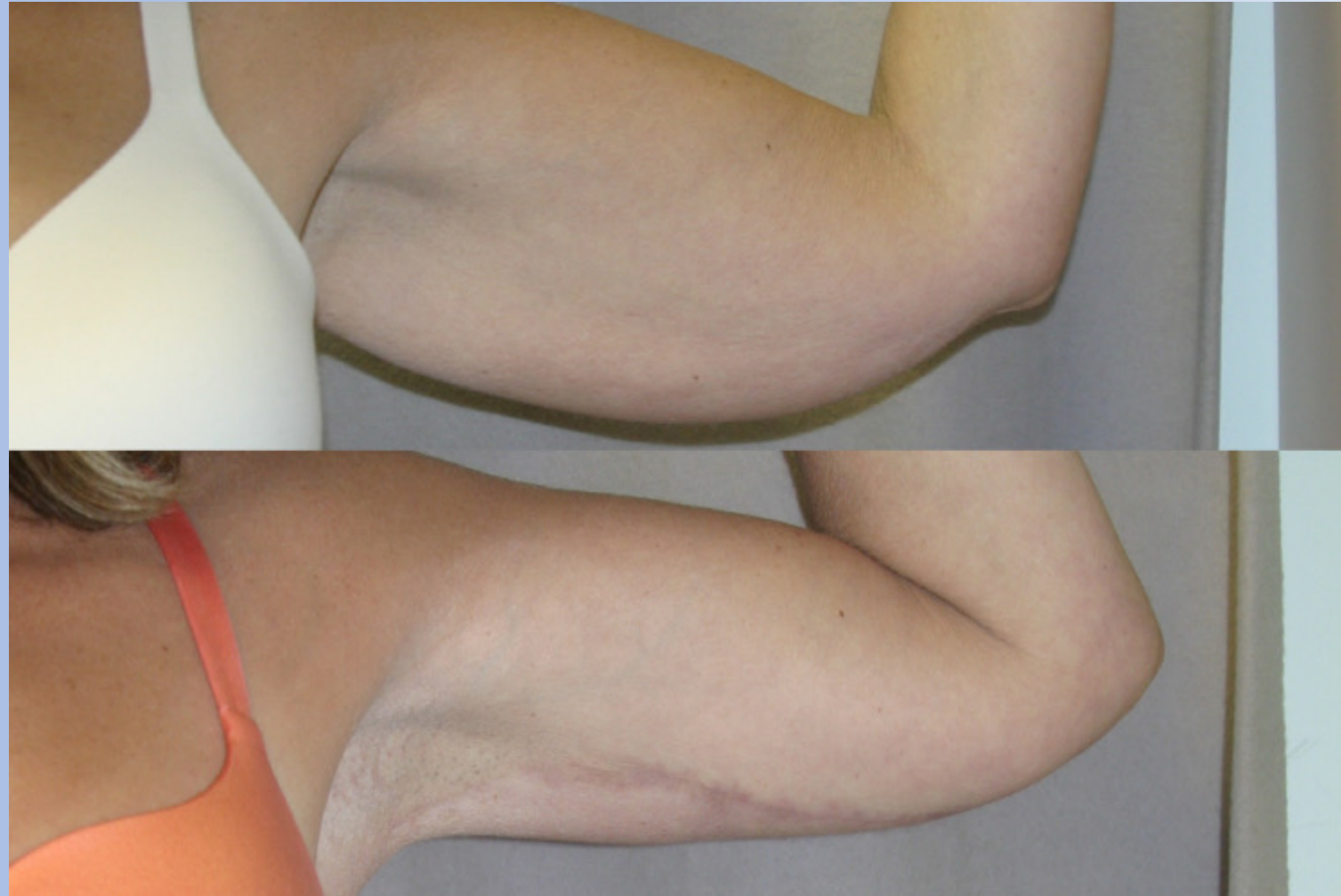Female Stage 2B - Brachioplasty



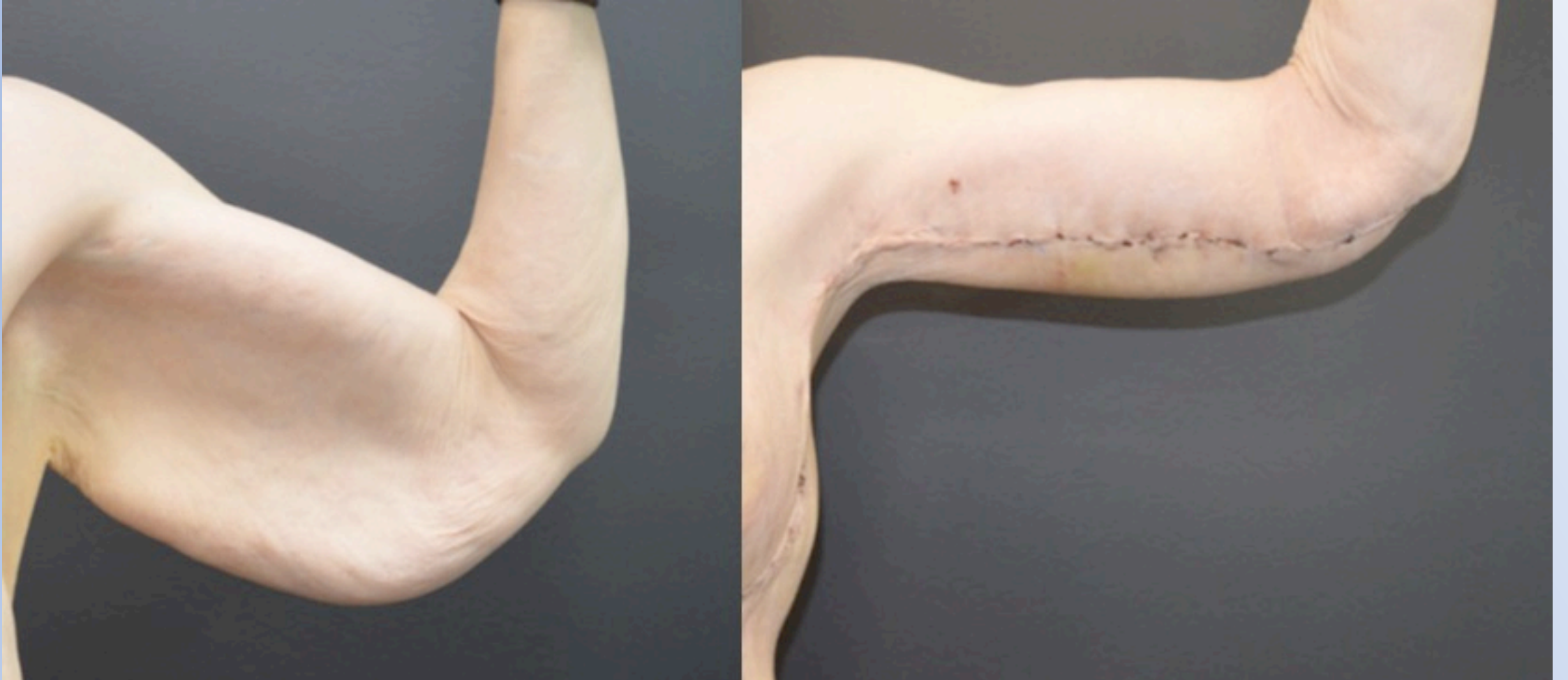Female Stage 2B - Brachioplasty



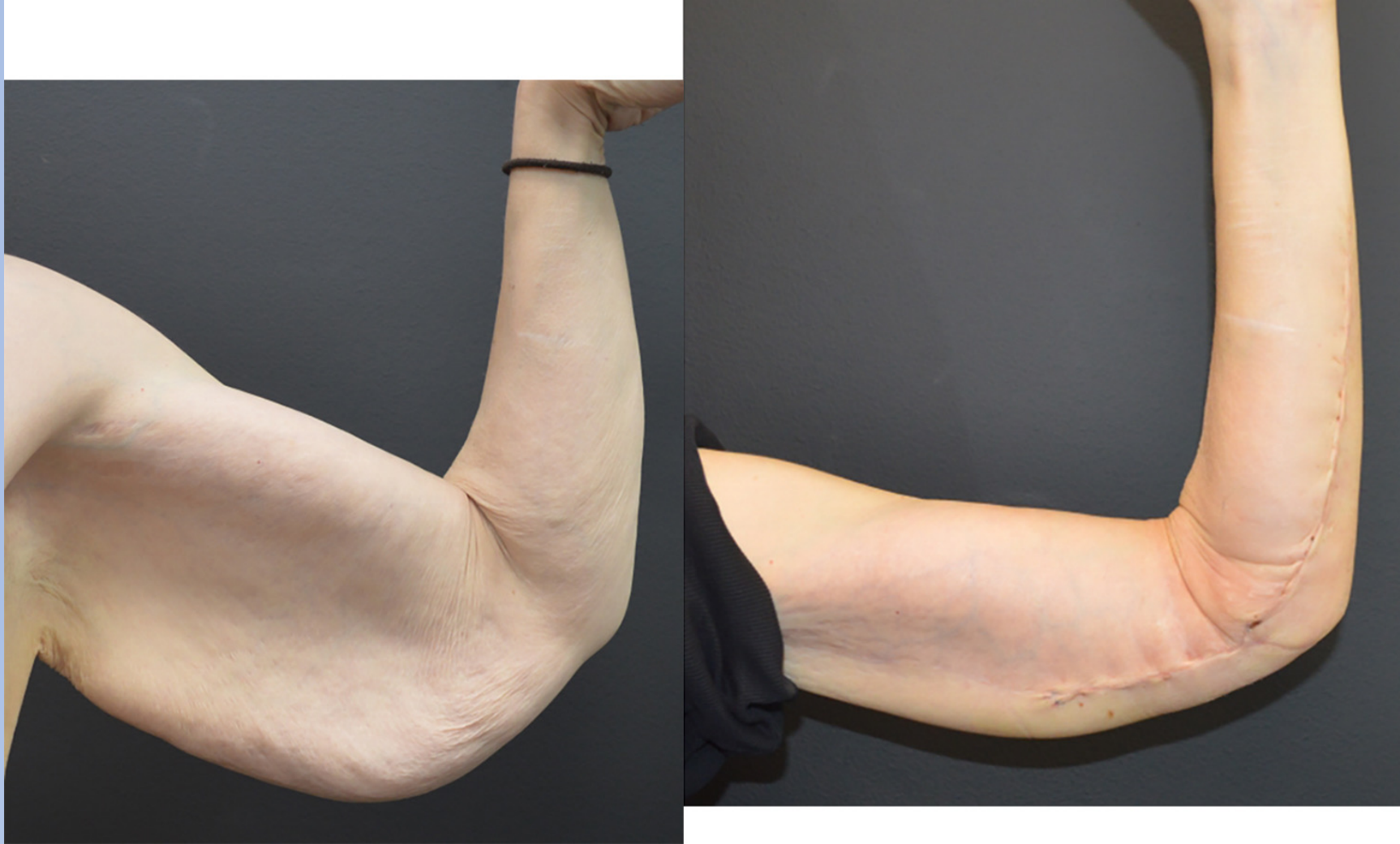Female Stage 2B - Brachioplasty



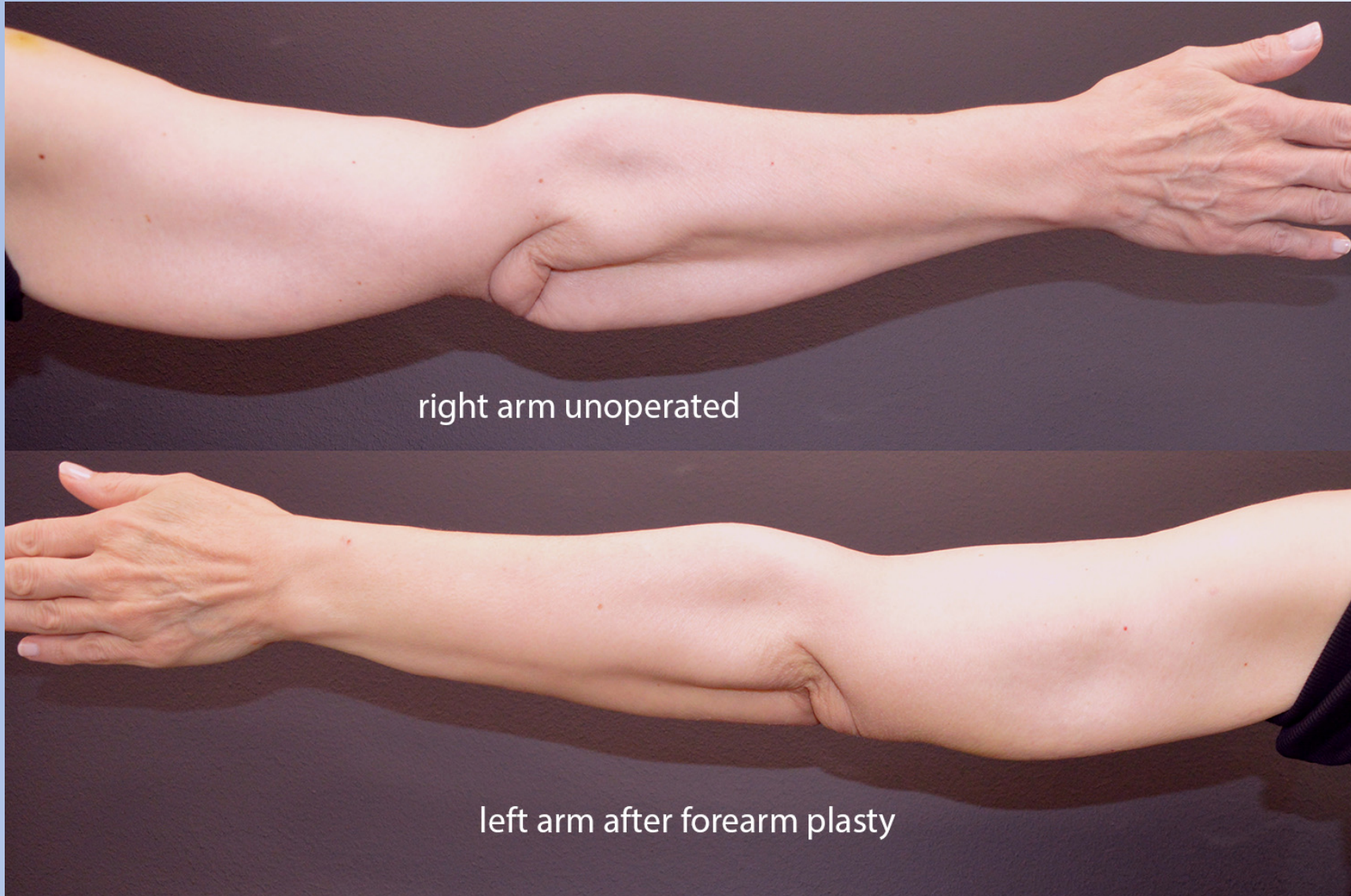
56-YEAR-OLD FEMALE BEFORE AND AFTER BCS: LOWER BODY LIFT, ABDOMINOPLASTY, BREAST LIFT AND BRACHIOPLASTY



56-year-old female forearm-plasty



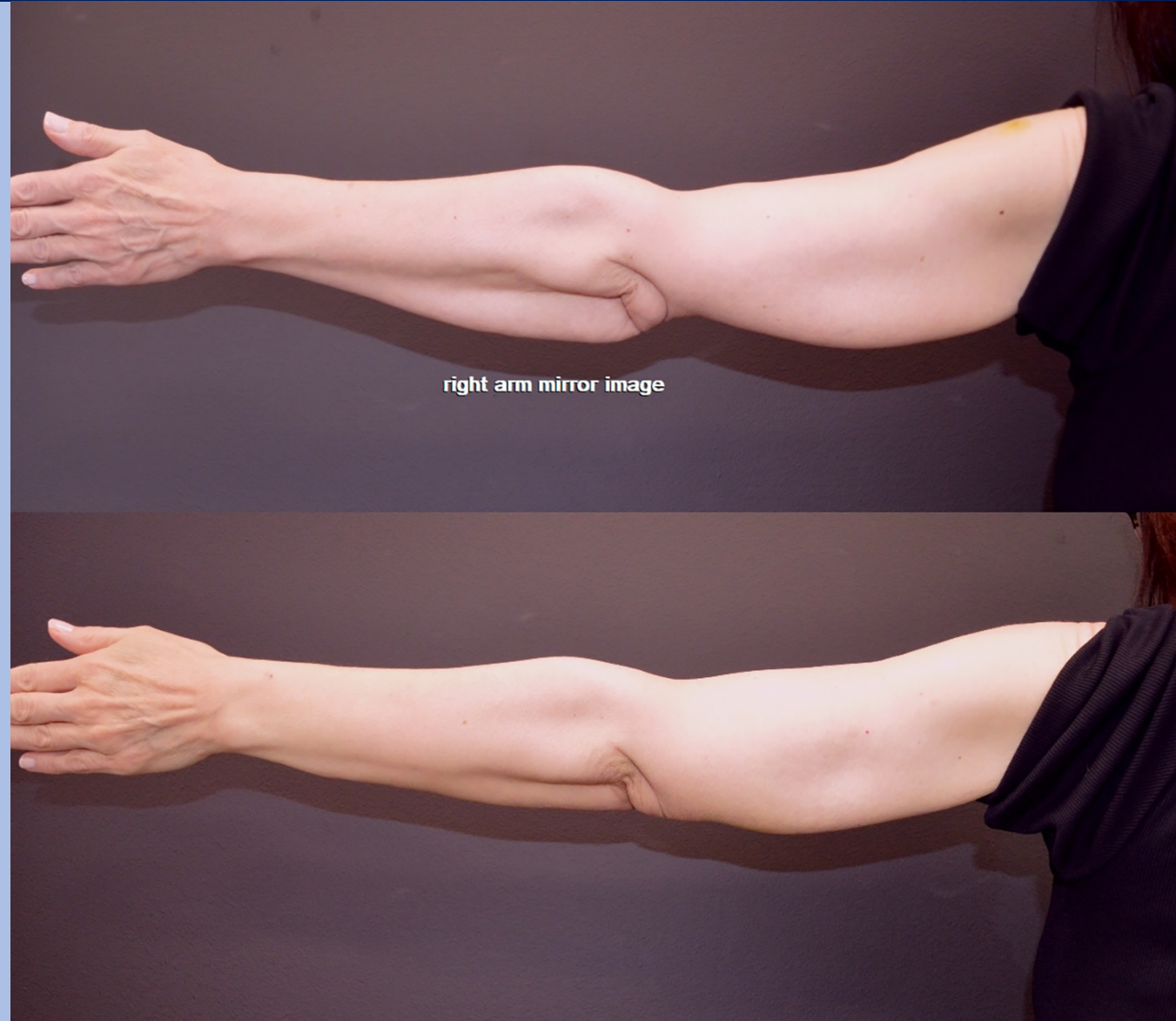
56-year-old female forearm-plasty



right arm unoperated

left arm after forearm plasty

56-year-old female forearm-plasty



right arm mirror image

**Stage
1**

LOWER BODY

**Stage
2A**

UPPER BODY

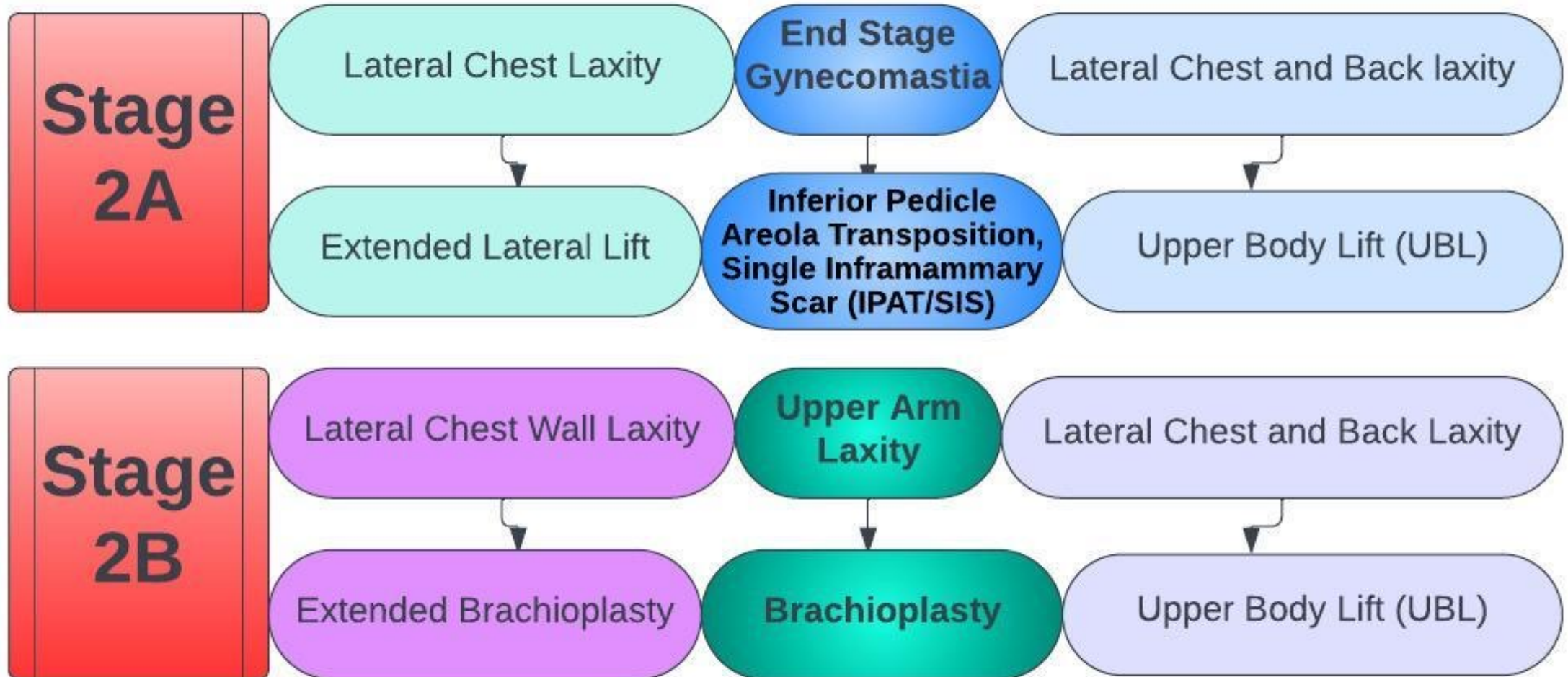
**Stage
2B**

UPPER EXTREMITY

**Stage
3**

LOWER EXTREMITY

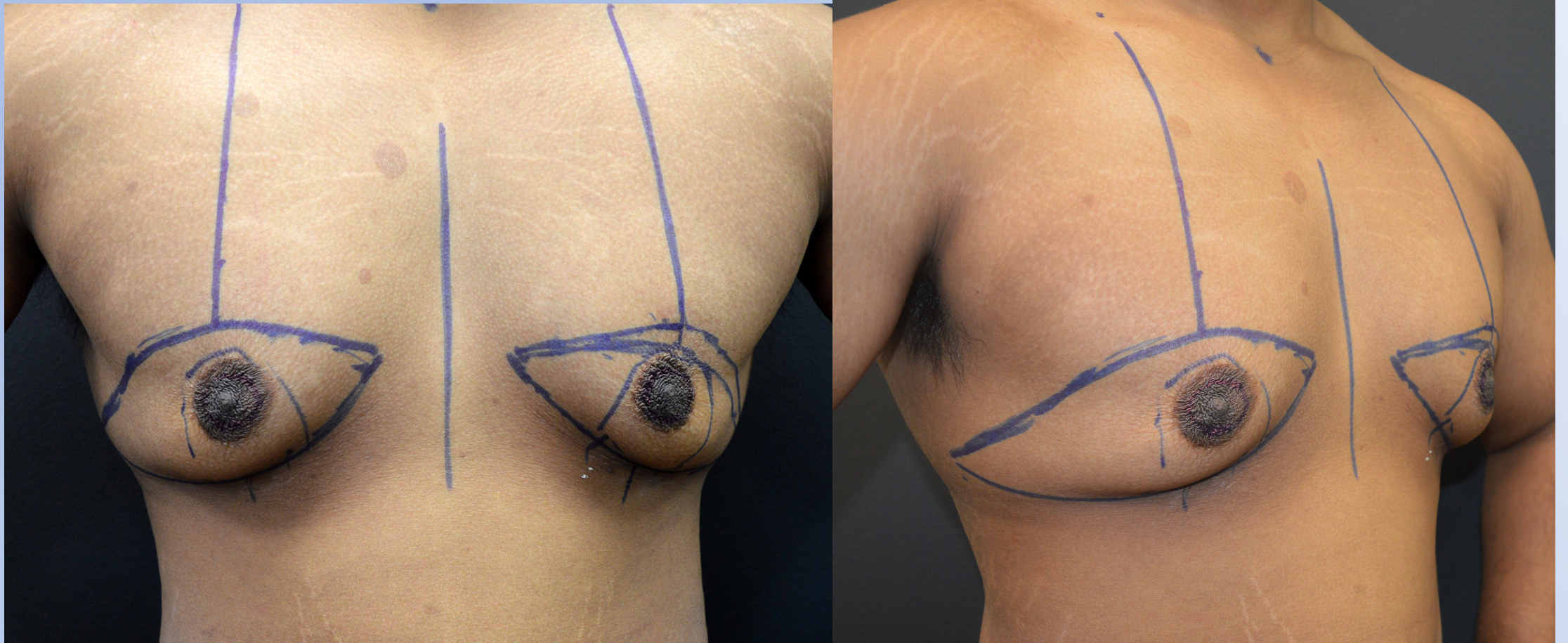
Male Stage 2A / 2B



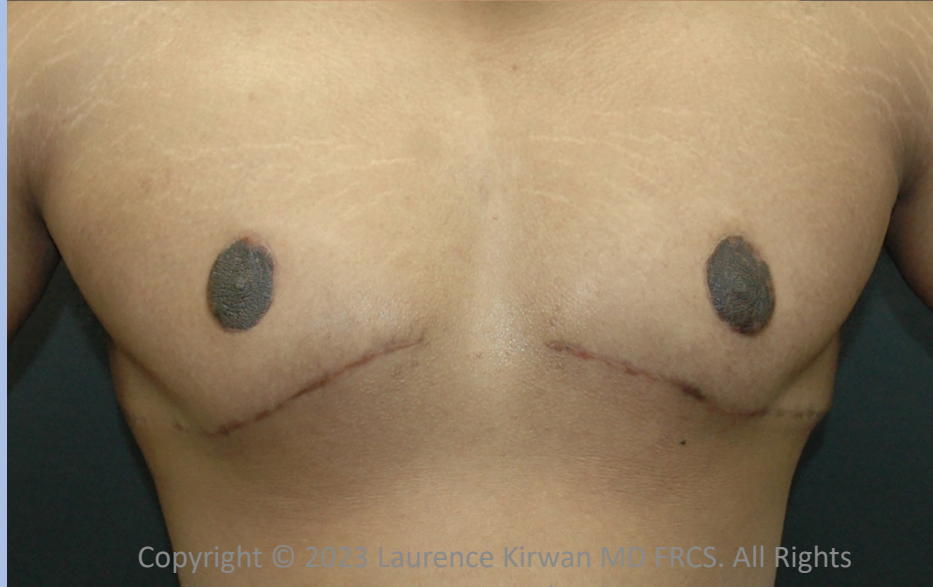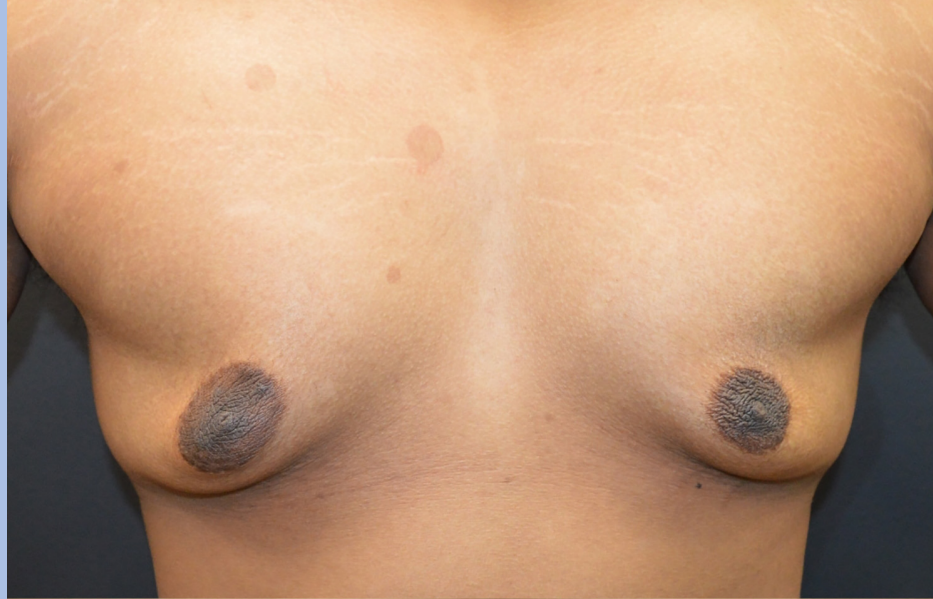**Management of 'End Stage
Gynecomastia' after massive weight
loss.**

**Inferior Pedicle Areola
Transposition, Single Inframammary
Scar (IPAT/SIS).**

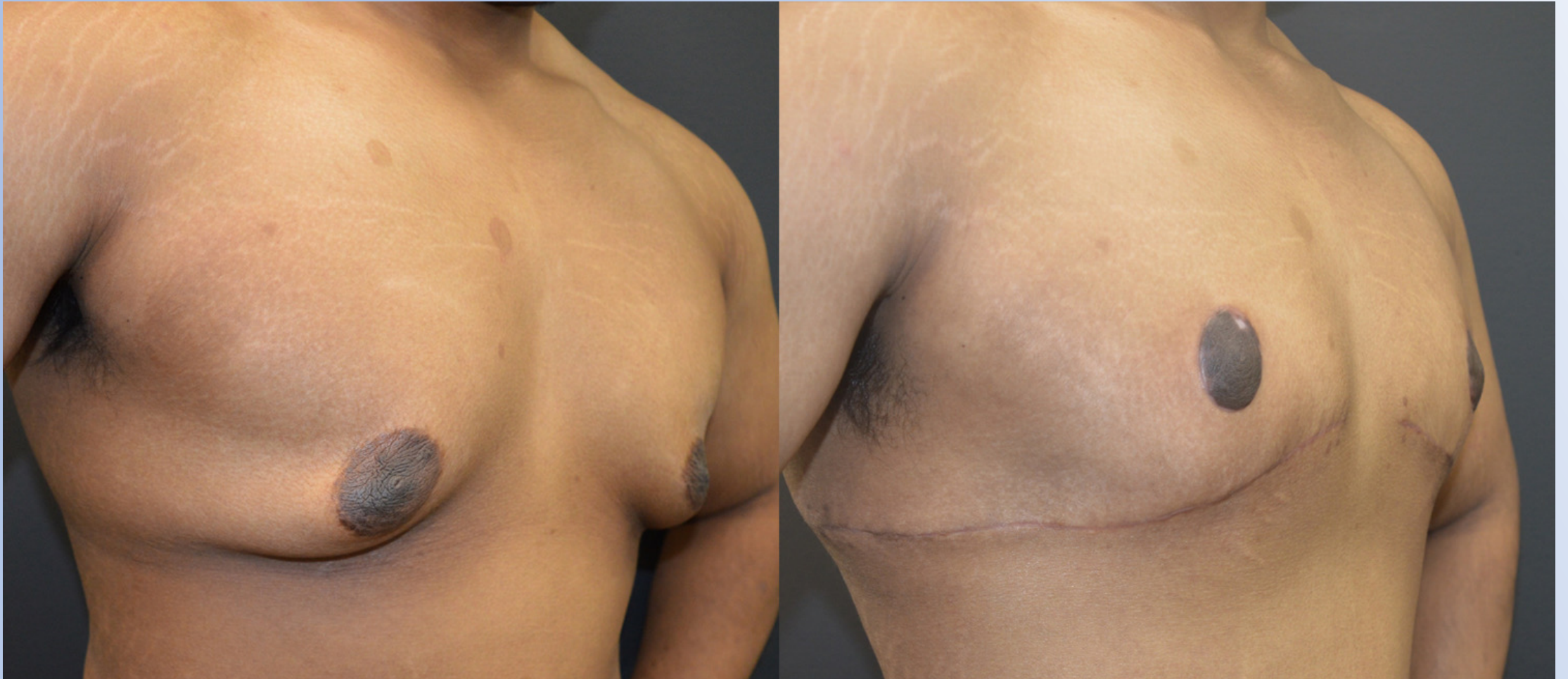Stage 2A, Inferior Pedicle Areola Transposition, Single Inframammary Scar (IPAT/SIS).



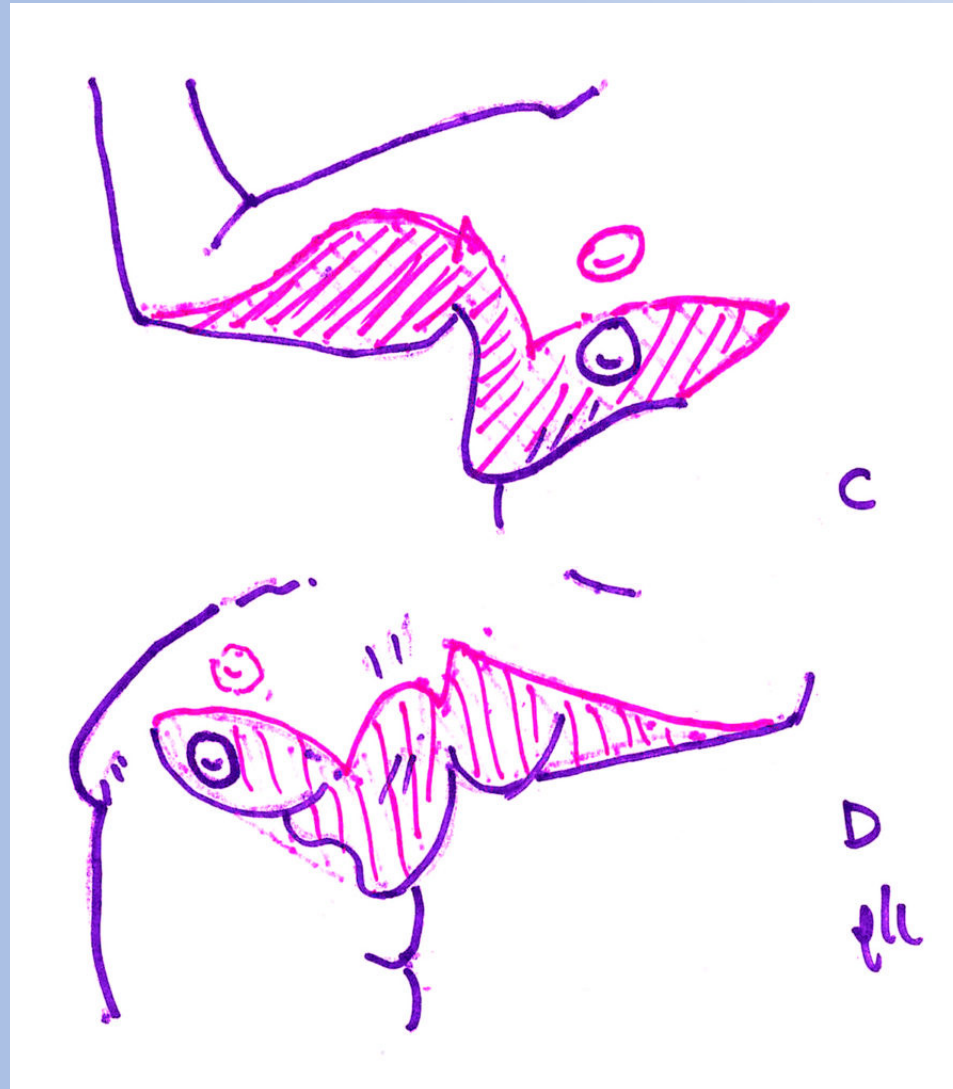
Stage 2A, Inferior Pedicle Areola Transposition, Single Inframammary Scar (IPAT/SIS).



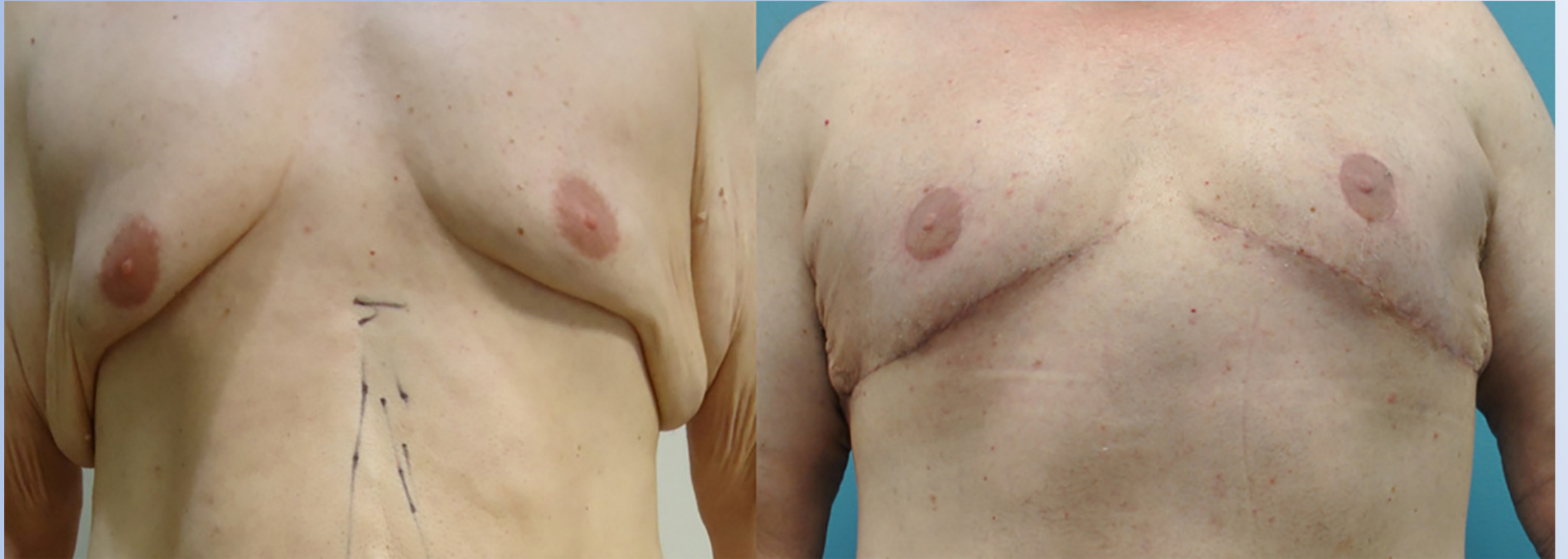Stage 2A, Inferior Pedicle Areola Transposition, Single Inframammary Scar (IPAT/SIS).



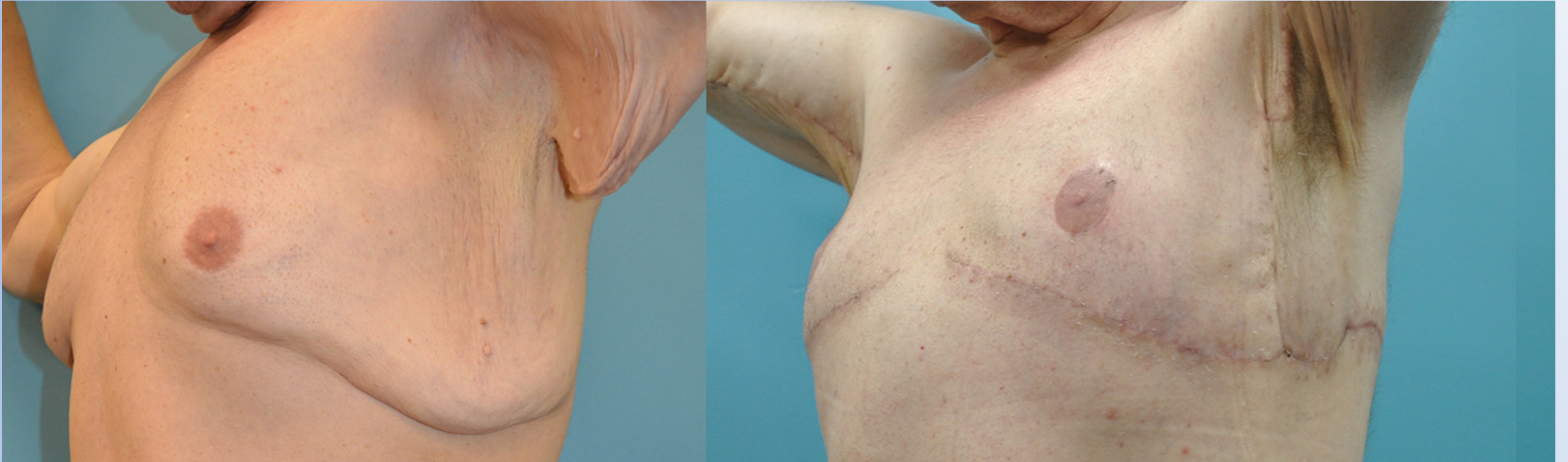Stage 2A & 2B , Inferior Pedicle Areola Transposition, Single Inframammary Scar (IPAT/SIS) & Extended Brachioplasty



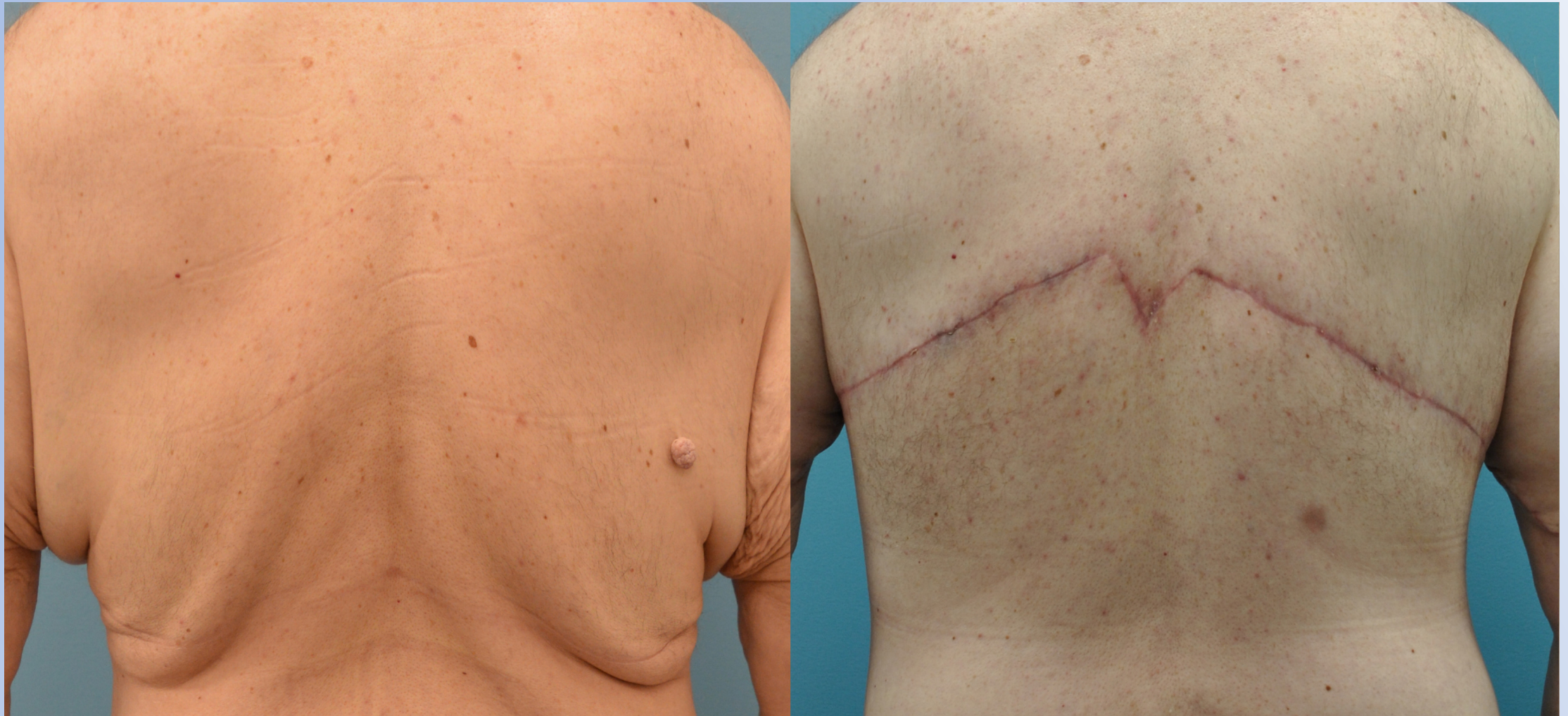Stage 2A & 2B , Inferior Pedicle Areola Transposition, Single Inframammary Scar (IPAT/SIS) & Extended Brachioplasty



Stage 2A & 2B , Inferior Pedicle Areola Transposition, Single Inframammary Scar (IPAT/SIS) & Extended Brachioplasty



Stage 2A & 2B , Inferior Pedicle Areola Transposition, Single Inframammary Scar (IPAT/SIS) & Extended Brachioplasty



**Stage
1**

LOWER BODY

**Stage
2A**

UPPER BODY

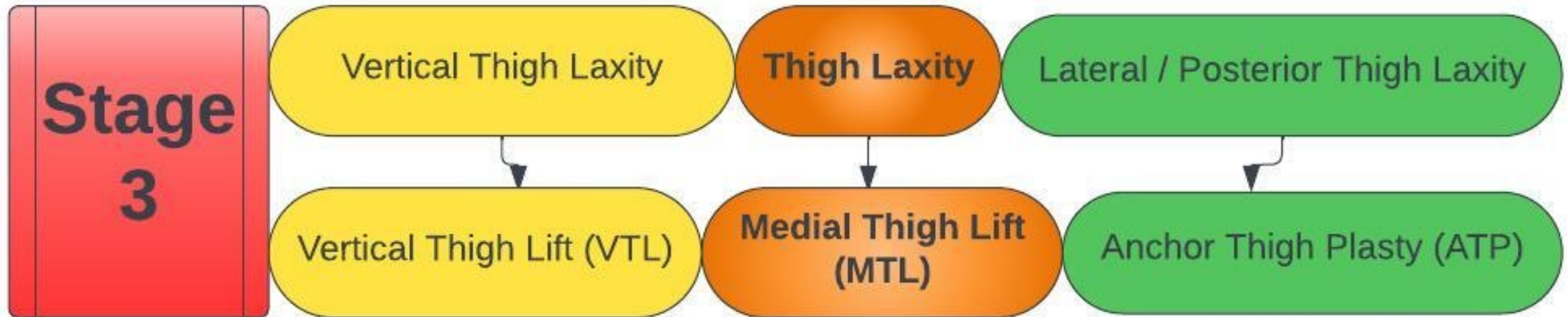
**Stage
2B**

UPPER EXTREMITY

**Stage
3**

LOWER EXTREMITY

Stage 3



Stage 3

Kirwan L. Anchor Thighplasty. *Aesthetic Surgery Journal*, 24/1 pp. 61-64, January/February 2004

Anchor Thighplasty

In the anchor thighplasty technique, the medial thigh lift is extended posteriorly into the infragluteal crease. The advantage is that the posterior thigh is lifted and ptosis of the caudal buttock can be corrected. Patients with buttock ptosis and medial thigh skin laxity without lateral thigh redundancy are ideal candidates. (*Aesthetic Surg J* 2004;24:61-64)

The aesthetic buttock has a symmetrical curvilinear fold that ends at the junction of the lateral thigh

hooks: Two represent the buttock creases and the third extends between the inner thighs. In this technique, the medial thigh lift is extended posteriorly into the infragluteal crease; the advantage is that the posterior thigh is lifted and ptosis of the caudal buttock can be corrected. The procedure can be per-



Laurence Kirwan, MD,
Norwalk, CT, is a board-certified
plastic surgeon and an ASAPS
member.

KIRWAN
PLASTIC SURGERY

Stage 3: Anchor Thigh Lift

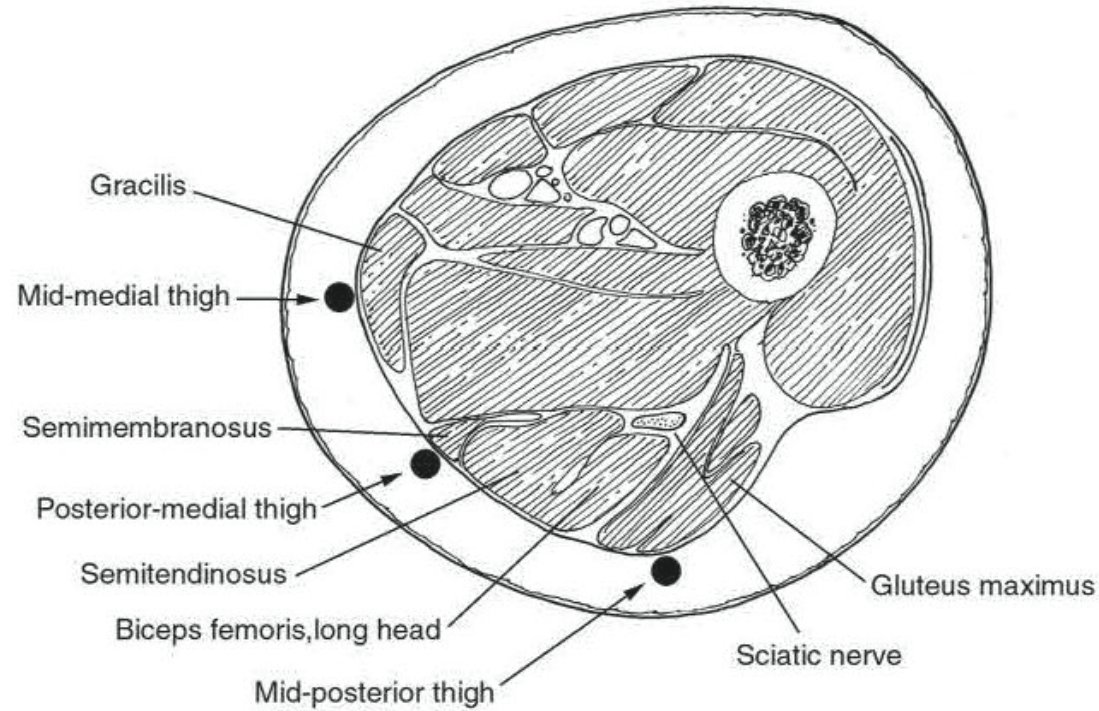
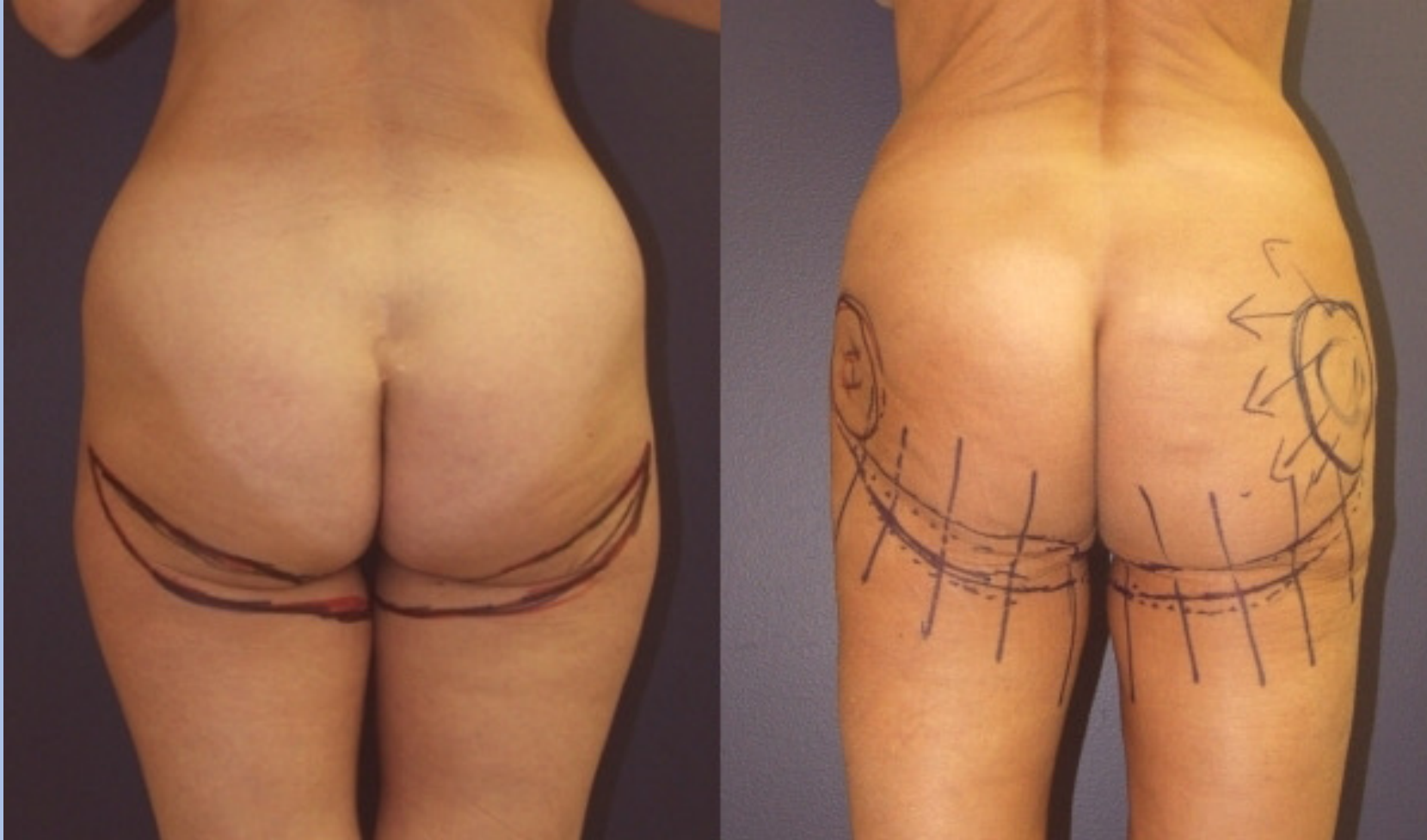
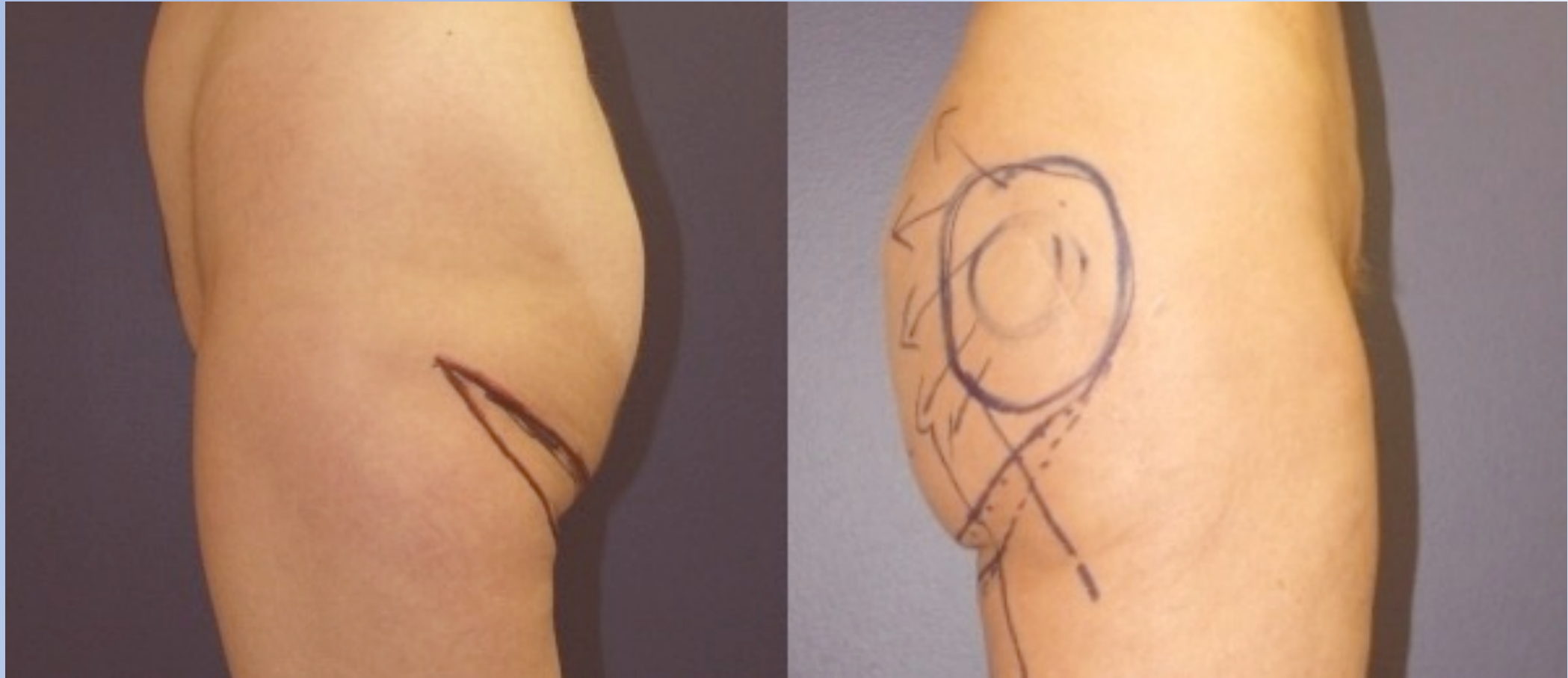


Figure 4. The 3 key points of suture suspension are the midmedial thigh, the midposterior thigh, and the posteromedial thigh. Points of suture suspension are marked.

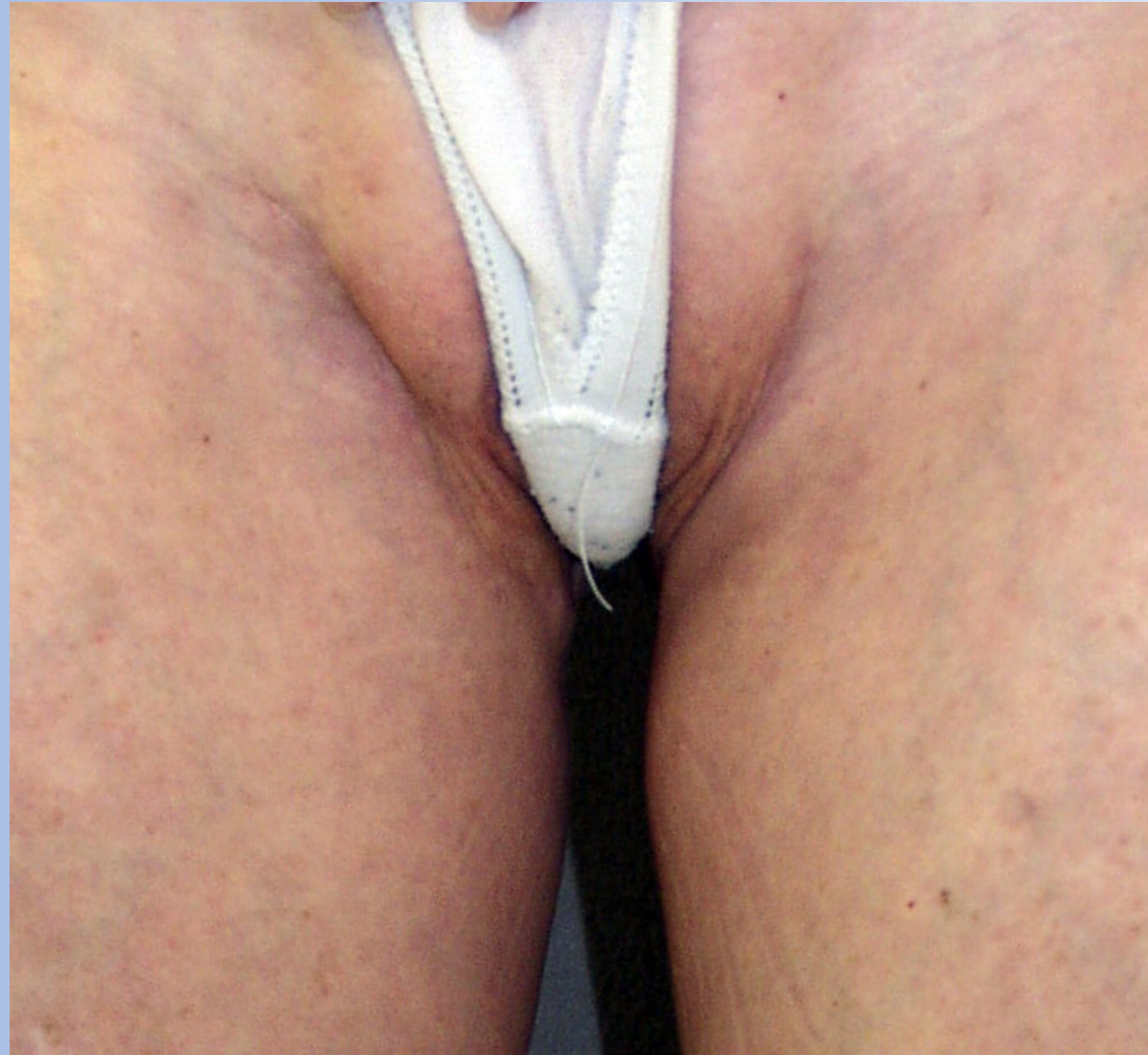Stage 3: Anchor Thigh Lift



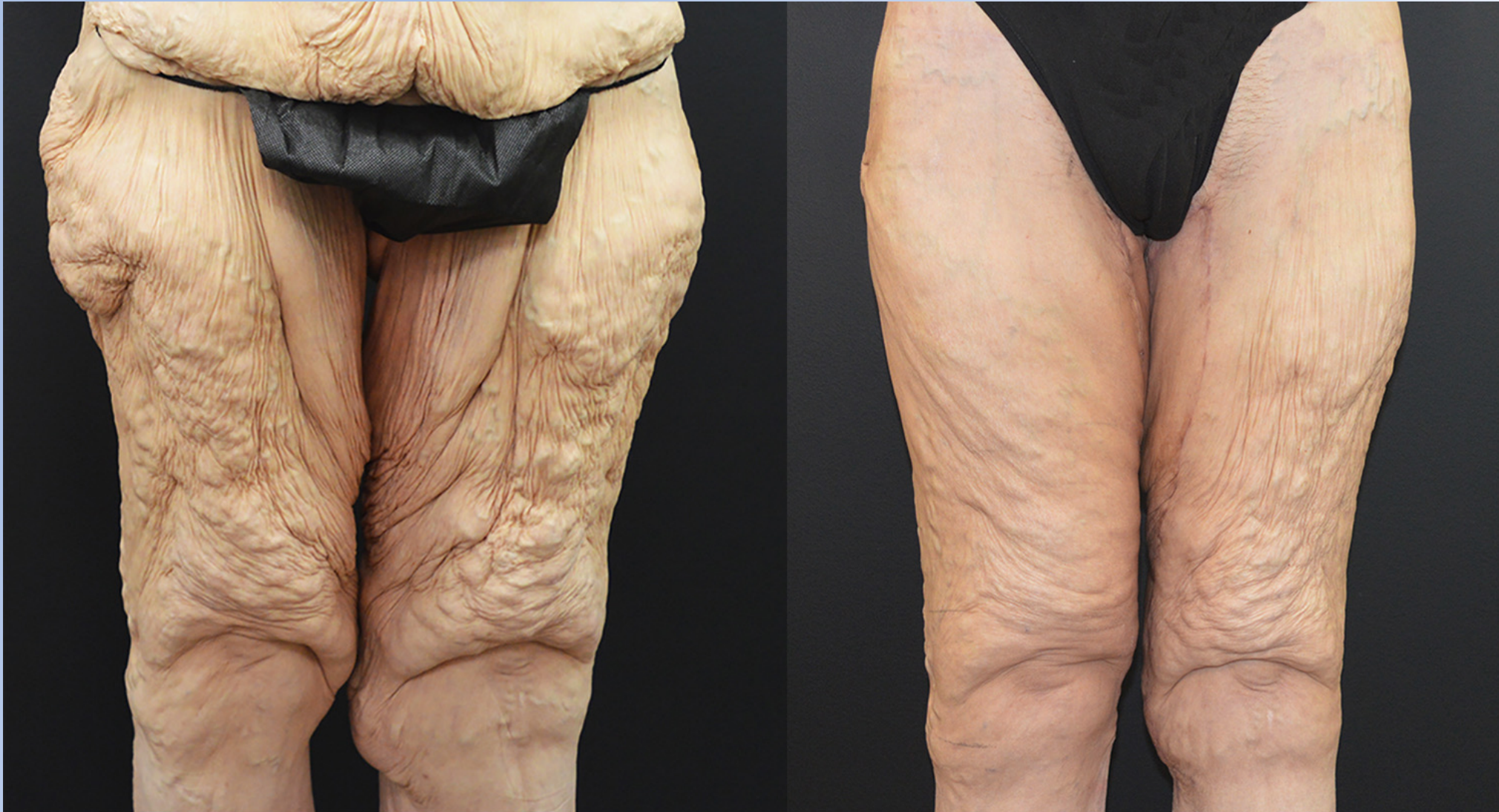Stage 3: Anchor Thigh Lift



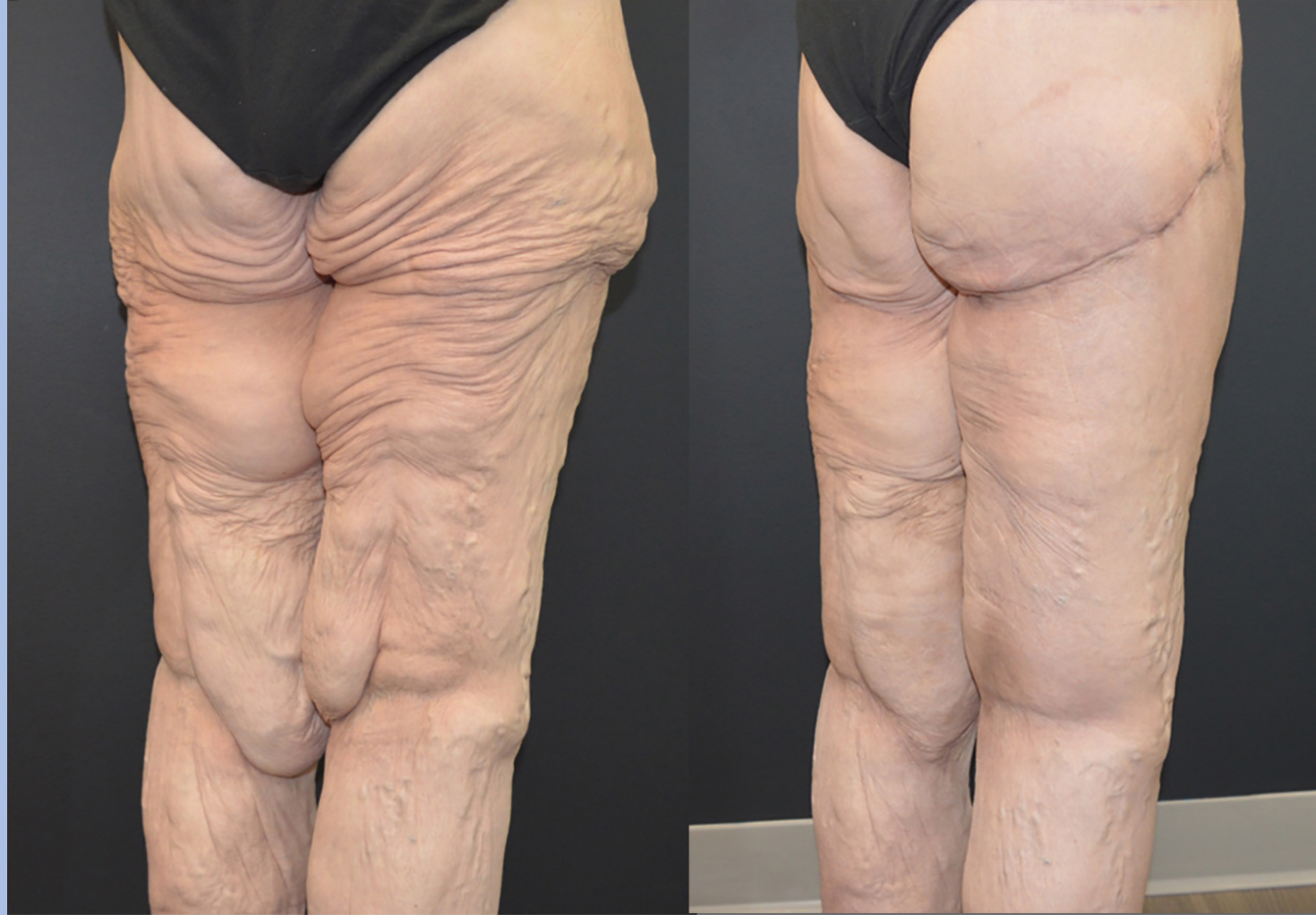Stage 3: medial thigh lift extension of anchor thigh lift



Stage 3: Spiral Vertical Thigh Lift

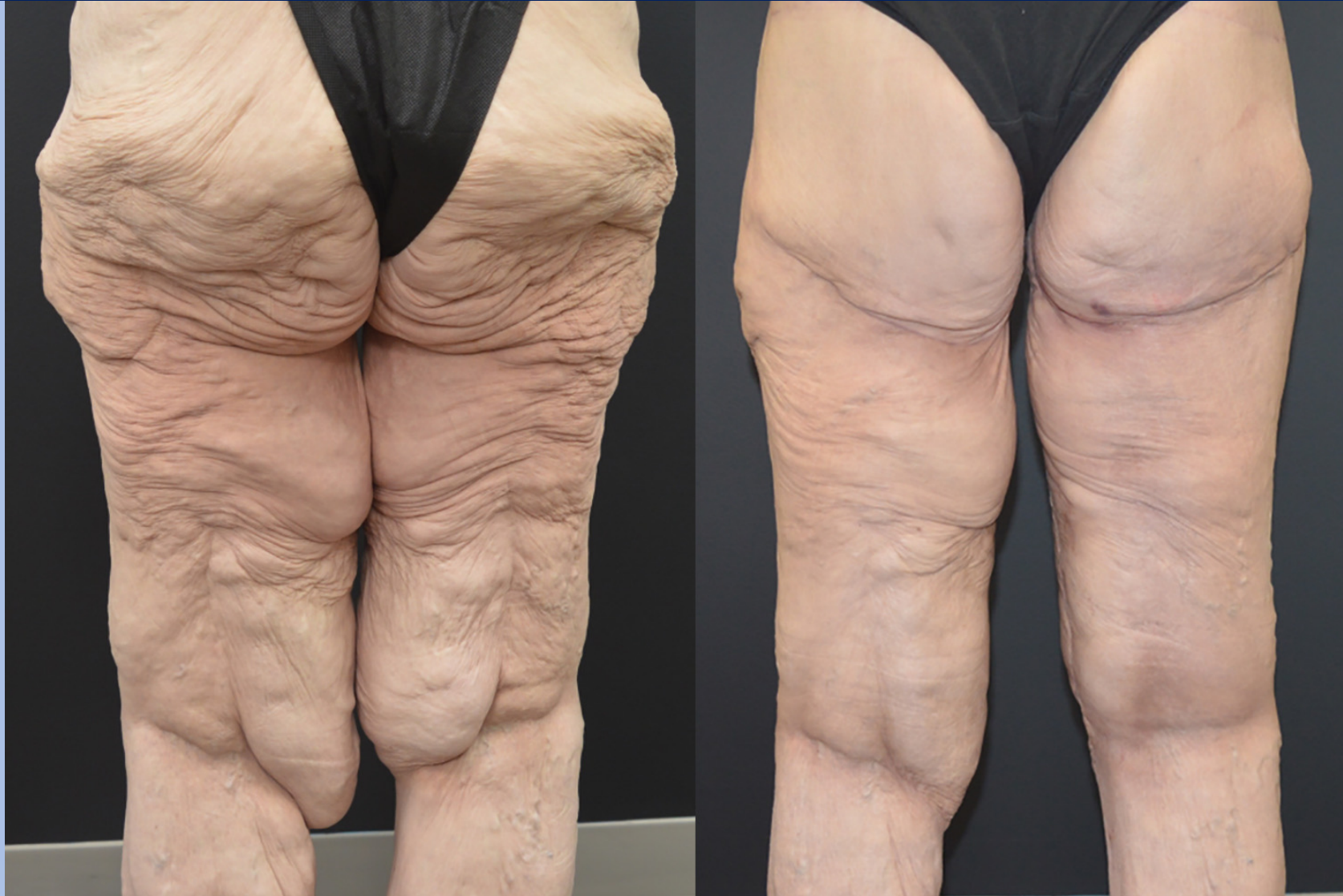

Stage 3: Spiral Vertical Thigh Lift

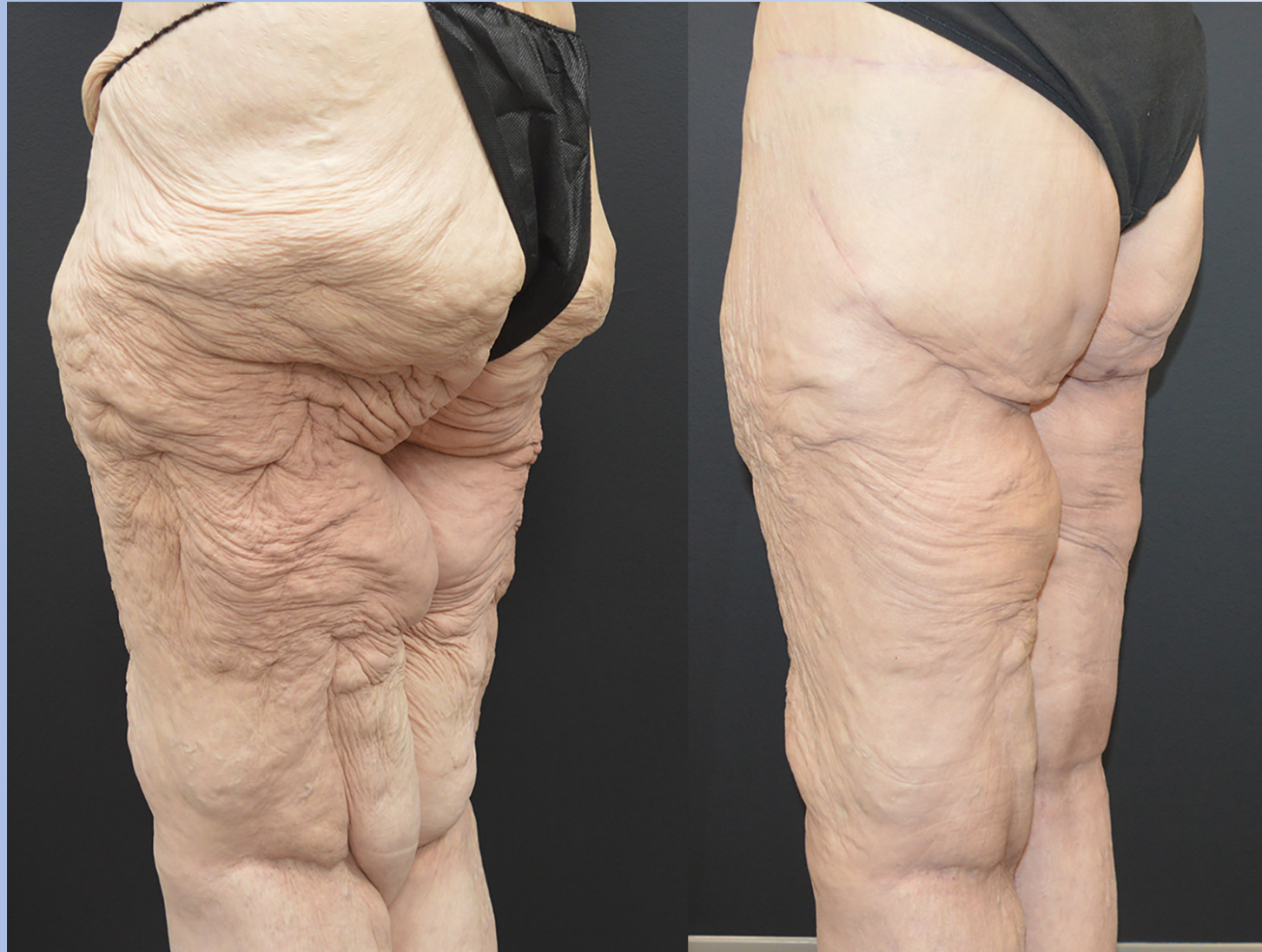

Vertical Thigh Lift and Anchor Buttock lift

Stage 3: Spiral Vertical Thigh Lift



Stage 3: Spiral Vertical Thigh Lift



Body Contouring Surgery Guide to Management

Laurence Kirwan MD
Grand Rounds, Norwalk Hospital
September 20, 2023

