

# Augmentation of the Ptotic Breast: Simultaneous Periareolar Mastopexy/ Breast Augmentation

Laurence Kirwan, MD

**Background:** *Submusculofascial augmentation of the ptotic breast can result in a "double-bubble" appearance, because a submusculofascial implant will lay superior to the ptotic gland. Subglandular augmentation in a ptotic breast avoids a "double-bubble" but will aggravate the preexisting ptosis.*

**Objective:** *The purpose was to review the technique of augmentation of the ptotic breast with a submusculofascial implant and simultaneous periareolar mastopexy.*

**Methods:** *Twenty-three patients were treated with the technique of simultaneous periareolar mastopexy/breast augmentation over a period of 18 months.*

**Results:** *This technique avoids the "double-bubble" appearance and leaves a minimal periareolar scar. There was one complication, a case of partial areolar necrosis. The most common errors in surgical technique were inadequate elevation of the nipple-areolar complex, inadequate periareolar skin excision, and the use of too small an implant.*

**Conclusions:** *Simultaneous periareolar mastopexy/breast augmentation is useful for augmenting the ptotic breast when augmentation alone will fail to give a satisfactory aesthetic result.*

One of the major drawbacks of submusculofascial augmentation of the ptotic breast is a "double-bubble" deformity (Figure 1). If a Wise pattern<sup>1</sup> mastopexy is added to correct the ptosis, there are additional vertical and transverse submammary scars.

Many authors have described augmentation combined with periareolar mastopexy. Regnault<sup>2</sup> in 1976 described a periareolar skin excision combined with a "V" excision at the lower portion, placing an implant in a submusculofascial location. Owsley<sup>3</sup> in 1978 described a simultaneous mastopexy and augmentation for correction of the small ptotic breast by use of primary augmentation with "tailor-tacking" and skin excision in an inverted "T" pattern. He preferred to use smaller implants and place them in a submammary pocket. Gruber and Jones<sup>4</sup> in 1980 described the "donut" mastopexy by use of a periareolar skin excision without a purse-string suture. To minimize periareolar spreading, a wedge of skin was excised from the inferolateral aspect of the areola. Augmentation was performed in the submammary space. De la Fuente and Martin del Yerro<sup>5</sup> in 1992 described the technique of simultaneous submuscular augmentation with periareolar mastopexy.

Dr. Kirwan is in private plastic surgery practice in Norwalk, CT, and London, England.

Presented to the Second European Congress on Advances in Cosmetic Surgery, London, England, on May 9, 1998. This article was also the subject of an instructional course at the Annual Meeting of the American Society of Plastic and Reconstructive Surgeons in Boston, MA, October 1998.

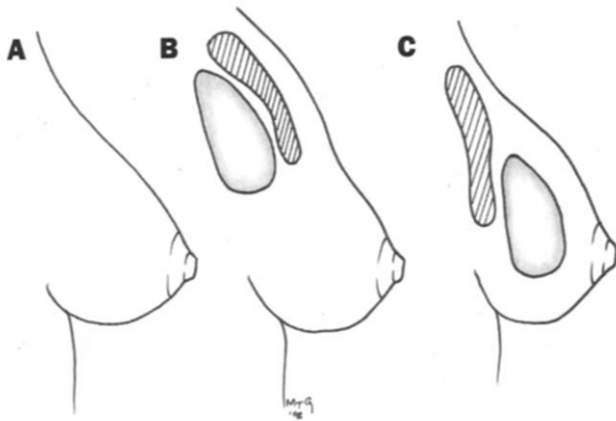
Accepted for publication Aug. 4, 1998.

Reprint requests: Laurence Kirwan, MD, 605 West Ave, Norwalk, CT 06850-4028.

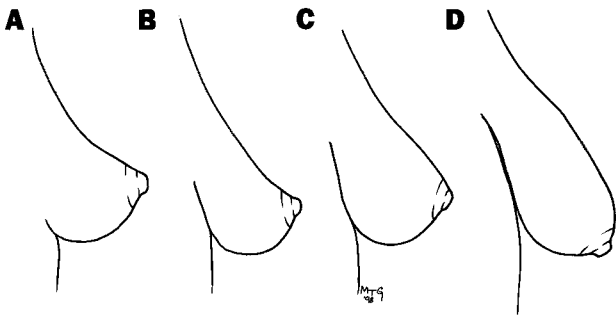
Copyright © 1999 by The American Society for Aesthetic Plastic Surgery, Inc.

190-820X/99/\$8.00 + 0

70/1/95455



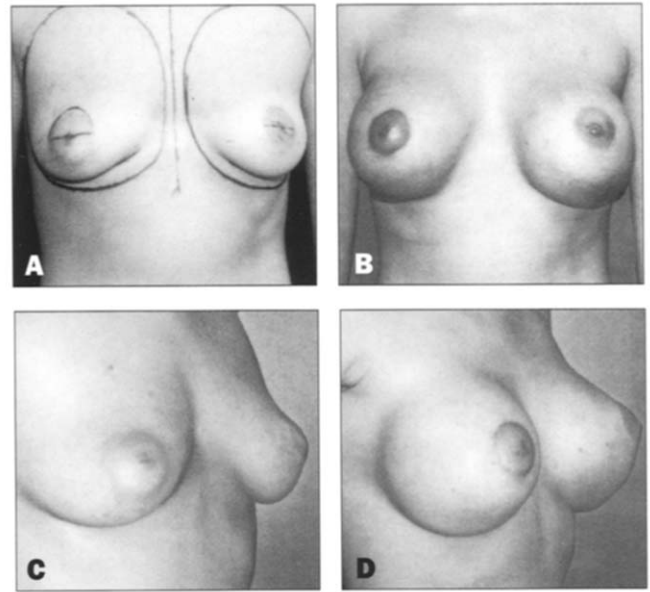
**Figure 1.** **A**, Grade II ptosis. **B**, Double-bubble deformity after insertion of implant in submusculofascial location. **C**, Increased ptosis after augmentation in subglandular location.



**Figure 2.** Classification of ptosis: **A**, Glandular ptosis. **B**, Grade I ptosis. **C**, Grade II ptosis. **D**, Grade III ptosis.

With regard to simultaneous periareolar mastopexy with breast augmentation, some surgeons have believed that postoperative correction of ptosis is primarily due to lowering of the inframammary crease and not to the periareolar mastopexy. Lowering of the inframammary crease is an integral part of a standard submusculofascial augmentation. Patients with glandular ptosis or grade I ptosis will do well with this technique alone. However, the results of such an augmentation are inadequate in grade II; hence, the “double-bubble” deformity.

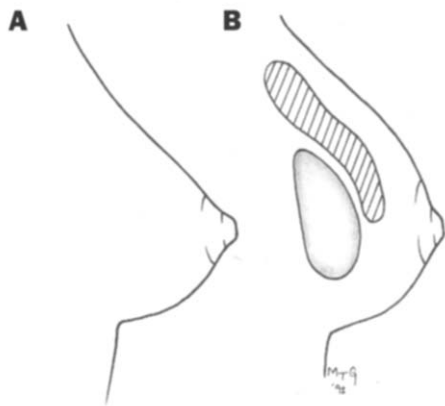
Ptosis is graded I to III (Figure 2) according to Regnault<sup>2</sup> and Bostwick.<sup>6</sup> Glandular ptosis refers to the descent of the glandular breast while the nipple remains above the inframammary crease. In such cases the upper breast is concave. Although the nipple is above the inframammary crease, it is still low compared with the normal nongravid breast in which the nipple is classically 7 cm above the inframammary crease.



**Figure 3.** **A** and **C**, Preoperative views of a 29-year-old female patient with glandular ptosis. **B** and **D**, Postoperative views after simultaneous periareolar mastopexy and breast augmentation.

Rather than using the current classification of ptosis, I have found it more informative to record the descent of the nipple (in centimeters) below the ideal position of 7 cm above the inframammary crease. It provides me with a specific measurement for the desired amount of nipple elevation. Simple augmentation can elevate the nipple by as much as 3 cm. Lowering of the inframammary crease by a further 2 cm will give the visual illusion of 5 cm of elevation (2 cm below the ideal level). Skin excision to elevate the nipple-areolar complex is an alternative to lowering of the inframammary crease when the preoperative nipple-areolar complex to inframammary crease distance is adequate for the planned implant size. The ideal nipple-to-inframammary crease distance in an augmented breast is 6 to 7 cm, depending on the implant radius. As the nipple descends further, skin excision, to elevate the nipple-areolar complex, is required, with or without modification of the inframammary crease. Therefore augmentation, with a sufficiently large implant, may result in an aesthetic breast in cases of glandular ptosis and minimal ptosis (grade 1).<sup>7</sup> However, periareolar mastopexy may still further enhance the final aesthetic result (Figure 3).

Augmentation of the grade II ptotic breast will result in a “double-bubble” appearance if the nipple-areolar complex is not also elevated with a skin excision. Therefore grade II ptosis, in which the nipple is more than 1 cm below the inframammary crease, requires a mastopexy. A periareo-



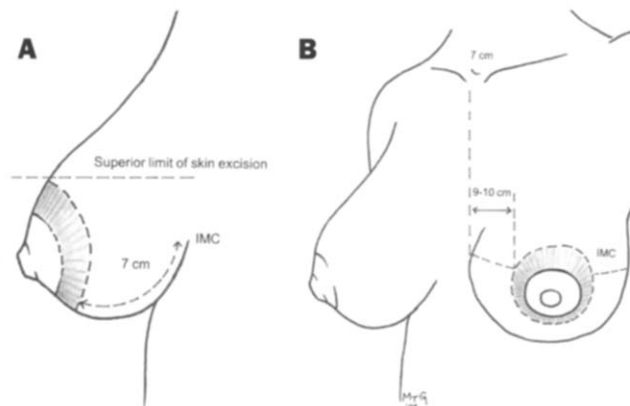
**Figure 4.** **A,** "Ideal" breast contour. **B,** Breast contour after simultaneous periareolar mastopexy and breast augmentation procedure.

lar mastopexy without an implant may result in a square-shaped breast and gives insufficient recontouring of the breast envelope. Benelli<sup>7</sup> has described a periareolar mastopexy combined with internal breast flaps without an implant. I have been unable to establish an adequate contour with this method alone. In grade III ptosis, periareolar mastopexy is usually inadequate to produce an aesthetically contoured breast. In such a case a Wise pattern mastopexy is performed. With a simultaneous augmentation, the inferior limb of the keyhole pattern should be 7 cm to accommodate the radius of the implant. If one attempts a subglandular augmentation of a ptotic breast even with a periareolar mastopexy, the ptosis will be aggravated over time (see below).

This article describes simultaneous periareolar mastopexy with breast augmentation in more detail and outlines a strategy for dealing with breast ptosis by degree. The augmented breast appears to defy gravity and aging when the implant is in a submusculofascial pocket (Figure 4). The implant, covered by the pectoralis major above and the submammary fascia below, has adequate support, which protects against late ptosis (in the case of a subglandular augmentation of a ptotic breast, ptosis increases with time and is proportional to the size of the implant). The periareolar incision results in minimal scarring. Twenty-three cases were performed over an 18-month period. The minimum follow-up is 6 months and the maximum 2½ years. Preoperative markings and surgical technique are discussed. The surgical strategy is explained, and representative cases and complications are shown.

### Preoperative Markings

The patient is marked in both the standing and supine



**Figure 5.** Preoperative markings. **A,** Standing position. **B,** Supine position. (IMC = Inframammary crease.)

positions (Figure 5). With the patient in the standing position the midline is drawn from the suprasternal notch to the xiphisternum. The breast meridian is marked joining a point 7 cm lateral to the suprasternal notch to the midpoint of the breast. The inframammary crease is marked. Asymmetries of the inframammary crease are noted. The limits of the new pocket are outlined. The inferior portion of the pocket is determined by the new diameter of the implant and is usually 1 to 2 cm below the existing inframammary crease. The new position of the nipple is 2 cm above the existing inframammary crease. Goulian's technique<sup>8</sup> of elevating the patient's arms high above the head to establish the aesthetic level of the nipple-areolar complex is helpful to determine correct nipple location. With the arms elevated a mark is made at the midsternal point at the level of the nipple. The arms are then brought down, and a mark is made on the breast at the level of the midsternal marking to show the new level of the nipple.

With the patient in the supine position, the distance from the new inframammary crease to the inferior edge of the periareolar skin excision is evaluated. The inferior limit of the periareolar skin excision is determined so that the distance from the new areola margin to the inframammary crease is symmetrical, measured with the skin on moderate stretch. The distance from the inframammary crease to the inferior edge of the areola should be about 7 cm. No inferior modification of the inframammary crease is planned if this measurement is adequate, provided that the inframammary crease is normally placed and not abnormally high. In the case of a high inframammary crease, the inframammary crease should be lowered and the distance between the new inframammary crease and

the areola shortened to the required length by use of the periareolar skin excision.

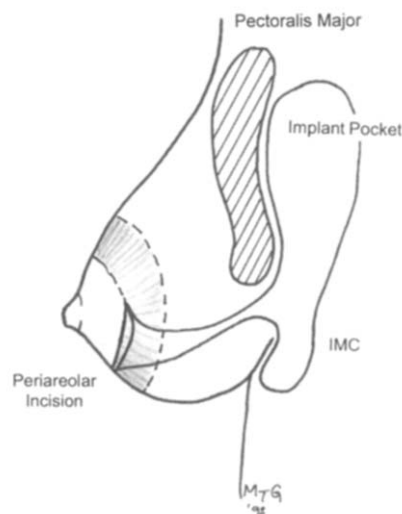
It is critical that the superior point of the areola is set at the time of marking and is symmetrical. The medial and lateral extent of the periareolar skin excision are also determined. The lateral-inferior, lateral-superior, and medial-inferior margins of the periareolar skin excision can be adjusted during surgery to tighten the skin envelope. However, the superior point of the skin excision is left unchanged. The medial point of the periareolar skin excision must be symmetrical and is 9 to 10 cm from the midline. After the implant has been placed, "tailor-tacking" can further tighten the overlying skin. This is to ensure symmetry and to remove redundant skin, mostly in the lower pole of the breast. Further skin excision is performed as necessary, avoiding any alteration in the superior point of the areola.

### Surgical Technique

Surgery is performed with the patient under general anesthesia. The patient is centered on the operating table with the arms abducted at 85 degrees. A stab incision is made in the axilla and dilated with a hemostat. Local infiltration anesthesia (for hemostasis and postoperative pain control) is placed through this wound posterior to the pectoralis major by use of a 60-mL syringe and an injection cannula. Infiltration is placed at the subfascial level laterally and lateral-inferiorly. The new areola diameter is outlined with a 45-mm cookie cutter with the areola on moderate tension. The periareolar incision is made (Figure 6). The superior and inferior limits of the planned skin excision are scored. If the skin excision is predictable, the periareolar skin is deepithelialized. If not, final skin deepithelialization is performed after placement of the implant and "tailor-tacking" of redundant skin.

An incision is made down to subcutaneous fat in the inferior half of the areola. The inferior and superior parts of the incision are retracted. The breast is grasped with the nondominant hand, and a number 10 blade is used to cut in a vertical direction through the breast tissue to the submammary space. The space may be dilated digitally to aid visualization of the inferior border of the pectoralis major muscle. The inferior edge of the pectoralis major is identified and elevated. The retropectoral pocket is entered with the index finger.

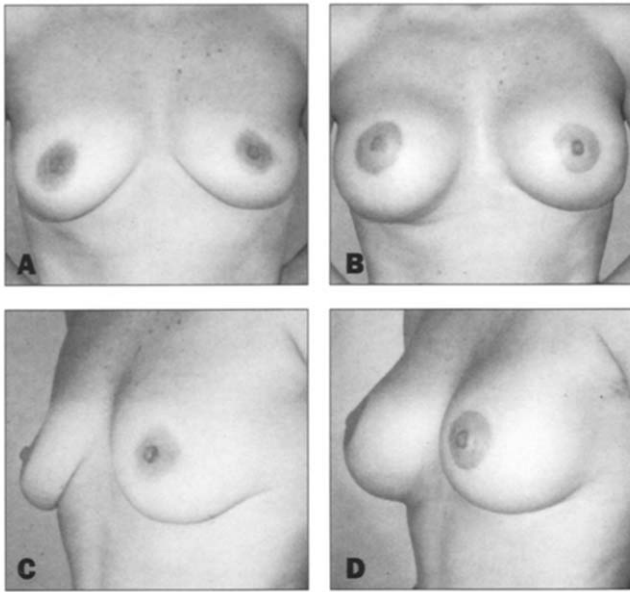
The finger is swept medially, superiorly, and laterally to aid elevation of the pectoralis minor. A retractor is



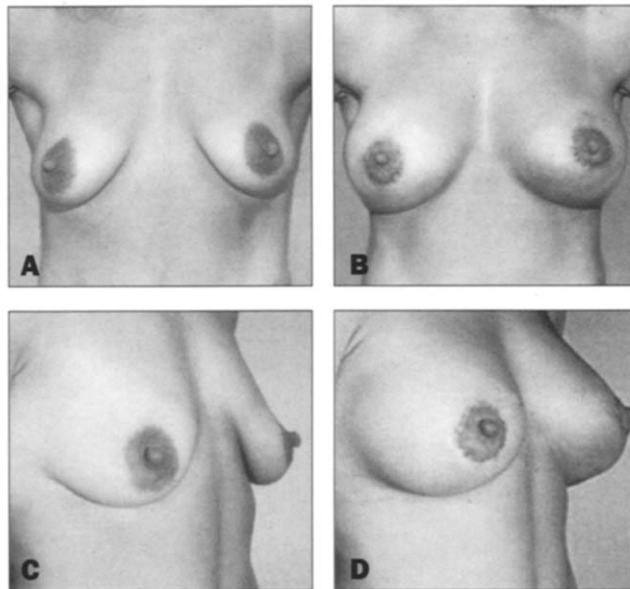
**Figure 6.** Diagram of surgical technique.

placed under the pectoralis major muscle and a tightly rolled sponge stick is used to dissect the superior and superior-lateral pocket. Further digital dissection is performed lateral-inferiorly and medial-inferiorly. The medial origin of the pectoralis major is divided. The remainder of the inferior-lateral pocket is dissected in the submammary plane. The pocket is enlarged to the limits of the preoperative markings. The implant pocket is packed, and the opposite side is dissected and also packed. After hemostasis is obtained, a sizer is inserted and inflated to the desired volume with air by use of the sterile delivery system (left unattached to the saline solution container). The same procedure is performed on the contralateral side, and the patient is elevated to the sitting position to check the implant level.

The breasts are viewed from the foot of the table. Any asymmetries are noted and marked with methylene blue. The patient is returned to the supine position. The pockets are modified with or without the sizers in place. Each permanent implant is washed in povidone iodine solution. The implant is deflated, and a one-way valve attached to the fill tube. The implant is placed in the pocket, making sure that it reaches to the most inferior and medial extent of the dissection. The center of the implant should be at the level of the inferior edge of the areola to avoid a downward pointing nipple and upper pole fullness. The implant is inflated to the desired volume, the fill tube is removed and the overlying tissues redraped over the implant. Placement of the implant is checked again with the patient in the upright position. The deep fascia and the breast tissue are closed.

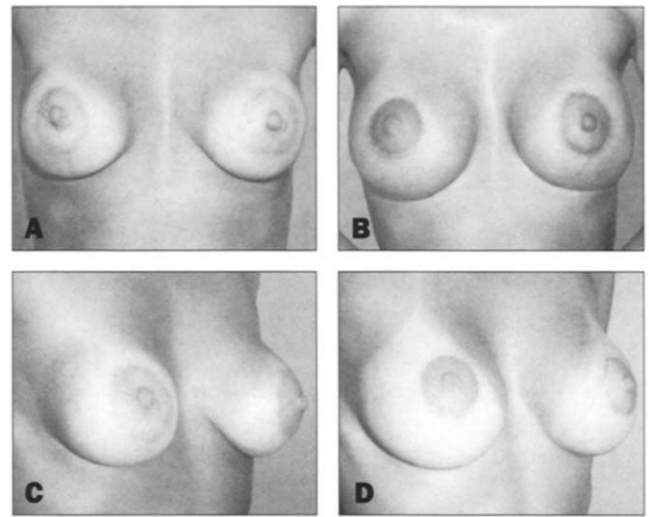


**Figure 7.** **A and C,** Preoperative views of a 44-year-old female patient with grade I ptosis. **B and D,** Postoperative views after simultaneous periareolar mastopexy and breast augmentation.



**Figure 8.** **A and C,** Preoperative views of a 31-year-old female patient with grade II ptosis. **B and D,** Postoperative views after simultaneous periareolar mastopexy and breast augmentation.

If the periareolar skin has not yet been excised, it is “tailor-tacked” to judge the amount of skin excision that is to be required. The situation is analogous to an upper lid blepharoplasty where one desires closure without residual wrinkling or laxity of skin. The skin of the breast should be firm and without laxity after the final closure. Skin excision



**Figure 9.** **A and C,** Preoperative views of a 30-year-old female patient with ptotic breast with subglandular implant. **B and D,** Postoperative views after simultaneous periareolar mastopexy and breast augmentation (implant now submusculofascial).

is performed. An incision is made in the deepithelialized area 0.5 cm from the skin edge, and undermining is performed for a distance of 1 to 4 cm beyond the skin edge from three to nine o'clock, to reduce tension and help recontour the breast envelope. A single subcutaneous 4-0 polyglyconate suture is placed at the 12-o'clock position. A periareolar suture is placed 5 mm from the wound edge by use of 3-0 monofilament nylon on a straight needle. The suture is tightened around a 45-mm cookie-cutter (the same size as the one used to originally reduce the size of the nipple-areolar complex). Although Benelli<sup>7</sup> recommends using a smaller template than the one initially used to prevent stretching of the periareolar scar, I prefer to use a template of the same size as the areola to avoid unnecessary puckering of the periareolar skin. The knot is buried in a superior pocket at the 12-o'clock position. The closure is completed with interrupted 4-0 polyglyconate subcutaneous sutures and a subcuticular 5-0 polyglyconate suture. The axillary stab incision is closed with a single 6-0 nylon suture. At the end of the procedure the implant position should rest at the limits of the preoperative marking, without external pressure.

### Representative Cases

See Figures 7 through 9.

### Complications

There was one complication in 23 patients, a case of par-

tial areolar necrosis that reepithelialized spontaneously. Partial loss of the areola may have been due to excessive tension. The most common error in surgical technique was one or more of the following: inadequate elevation of the nipple-areolar complex, inadequate periareolar skin excision, or the use of too small an implant. After wound healing is complete, some patients complain of residual puckering of the periareolar skin or overprojection of the areola. Both problems are corrected with a simple scar excision with removal of the purse-string suture and closure with interrupted dermal 4-0 polyglyconate and intracuticular 5-0 polyglyconate sutures.

### Summary

The following is a summary of my strategy for augmentation of the hypoplastic or atrophic ptotic breast. All implants are placed in a submusculofascial location.

1. Glandular ptosis: A larger implant (325 to 400 cc) is required to distend the ptotic breast or a smaller implant (220 to 275 cc) is combined with a periareolar mastopexy. The size of the implant is relative to the diameter of the breast.
2. Grade I ptosis: A larger implant (minimum size 325 cc or larger) alone or a smaller implant combined with a periareolar mastopexy is used.
3. Grade II ptosis: Simultaneous periareolar mastopexy and breast augmentation procedure is required to avoid a "double-bubble" appearance. A larger implant (minimum size 325 to 350 cc) is preferred.

4. Grade III ptosis: Augmentation combined with a Wise pattern mastopexy.

### Conclusion

An approach is described for augmentation of the ptotic breast. A submusculofascial implant is combined with a periareolar mastopexy. This technique avoids the "double-bubble" appearance and leaves a minimal periareolar scar. The skin is redistributed in an even fashion and the periareolar scar is protected from stretching. Placement of the implant in a submusculofascial pocket avoids aggravation and late recurrence of ptosis. ■

### References

1. Wise RJ. Preliminary report on a method of planning the mammoplasty. *Plast Reconstr Surg* 1956;17:367-75.
2. Regnault P. Breast ptosis: definition and treatment. *Clin Plast Surg* 1976;3:193-203.
3. Owsley JQ Jr. Simultaneous mastopexy and augmentation for correction of the small, ptotic breast. *Ann Plast Surg* 1979;2:195-200.
4. Gruber RP, Jones HW Jr. The "donut" mastopexy: indications and complications. *Plast Reconstr Surg* 1980;65:34-8.
5. de la Fuente A, Martin del Yerro JL. Periareolar mastopexy with mammary implants. *Aesthetic Plast Surg* 1992;16:337-41.
6. Bostwick J. *Aesthetic and reconstructive breast surgery*. St. Louis: Mosby, 1983.
7. Benelli L. A new periareolar mammoplasty: round block technique. *Aesthetic Plast Surg* 1990;14:93-100.
8. Goulian D. Dermal mastopexy. *Clin Plast Surg* 1976;3:171-5.